

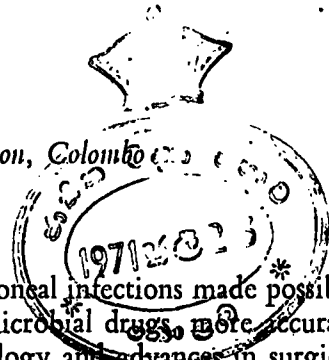
## The Surgical Anatomy of the Intraperitoneal Subphrenic Spaces

by

R. A. NAVARATNE

Department of Surgery, University of Ceylon, Colombo

(With six text figures)



As a result of the increasingly effective control of peritoneal infections made possible through the availability of a host of wide spectrum antimicrobial drugs, more accurate fluid and electrolyte therapy, improvements in anaesthesiology and advances in surgical technique, subphrenic abscess nowadays is dwindling towards an incidence which is sufficiently insignificant to make it noteworthy of record.

Ferguson (1956) quotes an incidence of subphrenic abscess of 0.05% in general surgical patients in British Hospitals. Up to 1962 the writer can recall of encountering only three subphrenic abscesses, the third of which was his own personal experience. This occurred in the latter part of November 1961 and followed a leak from the duodenal stump of a Polya-Hofmeister gastrectomy for a combined gastric and duodenal ulcer in a 42 year old Malay male, who recovered satisfactorily following evacuation of the pus from the pouch of Rutherford Morison through the bed of the right twelfth rib.

Apart from the salutary effect of making the author more conscious of the necessity for taking meticulous care in the closure of the transected duodenal stump (and perhaps of instituting drainage or duodenostomy in the case where more than an ordinary difficulty of closure was likely to enhance the chance of a leak in future gastric resections of a similar nature), it brought to light an interesting state of affairs which culminated in an even more interesting investigation, which is now the theme of this paper.

The subject of subphrenic abscess was brought under discussion sometime afterwards on the ward teaching round. Whilst the traditional and time honoured accounts of its aetiology and pathology went over smoothly, the rest of the discourse ran into snags when the surgical anatomy of the various potential intraperitoneal spaces below the diaphragm came under consideration. The writer's views of this aspect of the subject and those of his students (three of whom had culled their knowledge from three different and popular undergraduate texts) clashed sufficiently to make the situation difficult of elucidation and worthy of note.

The spur having been provided, a burrowing into the literature in search of clarity followed and the result was quite fascinating but hardly illuminating as the reward was increasing confusion rather than more lucidity.

The further one delved into authoritative works on the subject the less clear did the situation become and hence a halt was called at a round two dozen references, for a review of the data obtained. This group of authorities comprised general surgical texts, manuals of surgical pathology, surgical anatomy and operative surgery, both undergraduate and postgraduate, as well as the more extensive reviews of the subject in the literature.

The analysis of the pronouncements of these 24 authorities with respect to the location and boundaries of the various intraperitoneal subphrenic spaces made the following facts forcibly evident.

1. There was as much diversity as there was unanimity with respect to terminology in its application to an individual space. Three spaces had no less than 11 different names applied to each, another had 10, a fifth had 9 and another 6.

2. The number of spaces mentioned varied from 4 to 6. Some authors did not 'recognise' spaces mentioned by others in that they were apparently considered non-existent or were part of a neighbouring space. With respect to three spaces this absence of mention occurred 13, 6 and 3 times respectively and one space stood in 'isolation' in that it was specifically designated by only two authors.

3. The most remarkable fact was the tendency towards obscurity which resulted from the use of positional terms—anterior, posterior, superior and inferior and their various combinations—a situation which enhanced a lack of clarity which tended to make a mental picture of the space mentioned difficult of clear visualisation.

Reference to Tables 2 to 8 wherein each intraperitoneal space as described and named by Barnard in his classical paper (1908) is tabulated with the nomenclature as given by the various authorities (Table I) who were 'consulted', will make the above mentioned points abundantly clear.

TABLE I.

**Authors 'Consulted' on the Anatomy of the Subphrenic Spaces**

<i>Author/s</i>	<i>Reference Volume</i>
(A) Aird, I.	(1957). <i>A Companion in Surgical Studies</i> , p. 674 Edinburgh, Livingstone
(B) Anson, B. J. and Maddock, W. G.	(1952). <i>Callander's Surgical Anatomy</i> , p. 430, Philadelphia, Saunders
(C) Bailey, H.	(1958). <i>Emergency Surgery</i> , p. 342, Bristol, Wright.
(D) Bailey, H. and Love, McN.	(1962). <i>A Short Practice of Surgery</i> , p. 889, London, Lewis
(E) Berens, J. J., Howard, K. G. and Dockerty, M. B.	(1953). <i>Subphrenic Abscess</i> , <i>Surg. Gynec. &amp; Obst.</i> , 96, 463-470

- (F) Boyd, W. (1955). *Pathology for the Surgeon*, p. 278, Philadelphia, Saunders
- (G) Brain, R. H. F. (1958). *Textbook of Surgery*, ed. by Blackburn and Lawrie, p. 510, Oxford, Blackwell
- (H) Ellis, H. (1960). *Clinical Anatomy*, p. 64, Oxford, Blackwell
- (I) Farquharson, E. L. (1962). *Textbook of Operative Surgery*, p. 573, Edinburgh, Livingstone
- (J) Ferguson, J. H. L. (1956). *Textbook of British Surgery*, ed. by Souttar and Goligher, vol. 1, p. 337, London, Heinemann
- (K) Handfield-Jones, R. M. (1957). *The Essentials of Modern Surgery*, ed. by Handfield-Jones and Porritt, p. 584, Edinburgh, Livingstone
- (L) Harley, H. R. S. (1957). *The Management of Abdominal Operations*, ed. by Maingot, vol. 2, p. 1136, Edinburgh, Livingstone
- (M) Illingworth, C. F.W. and Dick, B. M. (1960). *Textbook of Surgical Pathology*, p. 536, London, Churchill
- (N) Maingot, R. (1961). *Abdominal Operations*, p. 850, London, Lewis
- (O) McCorrison, J. R. (1952). *Textbook of Surgery*, ed. by Moscley, p. 437, London, Kimpton
- (P) McGregor, A. L. (1957). *Synopsis of Surgical Anatomy*, p. 654, Bristol, Wright
- (Q) Mitchell, G. A. G. (1940). The Spread of Acute Intraperitoneal Effusions, *Brit. J. Surg.*, 28, 291-313
- (R) Nather, C. (1922). Der prae-oder retroperitoneale Weg zum subphrenischen Abscess als typische Operation, *Arch. f. klin. Chir.*, 122, 24-99
- (S) Oschner, A. and Graves, A. M. (1933). Subphrenic Abscess, *Ann. Surg.*, 98, 961-990
- (T) Sawyer, K. C. (1953). *Emergency Surgery*, ed. by Ficcaro, p. 815, Philadelphia, Davis
- (U) Shepherd, J. A. (1960). *Surgery of the Acute Abdomen*, p. 135, Edinburgh, Livingstone
- (V) Thorek, P. (1951). *Anatomy in Surgery*, p. 511, London, Lipincott
- (W) Wakeley, C. (1960). *Rose and Carless Manual of Surgery*, ed. by Wakeley, Harmer and Taylor, p. 1035, London, Bailliere, Tindall and Cox
- (X) Walker, R. M. (1950). *British Surgical Practice*, ed. by Ross and Carling, vol. 8, p. 104, London, Butterworths

The letter within parentheses before the author/s forms the key to subsequent TABLES 2 to 8

TABLE 2

**Right Anterior Subphrenic Space of Barnard****Boundaries**

Superior — dome of the right diaphragm

Inferior — right lobe of the liver

Anterior — communicates with general peritoneal cavity and right posterior space over the free anterior edge of the liver.

Posterior — right lateral ligament of the liver

Medial — falciform ligament

Lateral — communicates round margin of liver and extremity of right lateral ligament with right posterior space

<i>Author/s</i>	<i>Nomenclature</i>
A	right anterior
B	right suprahepatic with anterior and posterior divisions
C	right suprahepatic
D	right anterior
E	right anterior suprahepatic
F	right anterior
G	right suprahepatic
H	right anterior
I	right anterior
J	right anterior
K	right anterior subdiaphragmatic division
L	right suprahepatic
M	right anterior
N	right anterior superior
O	right superior anterior suprahepatic
P	right anterior
Q	right subphrenic
R	right upper anterior
S	right anterior superior
T	right anterior superior suprahepatic
U	right anterior
V	right superior anterior
W	right anterosuperior
X	right suprahepatic

TABLE 3

**Right Posterior Subphrenic Space of Barnard**


---

“Better known as the subhepatic pouch or right renal fossa . . . a pyramidal space transversely disposed beneath the overhanging margin of the liver . . . its base rests against the right lateral abdominal wall . . . its apex is formed by the upward slope of the margin of the left lobe of the liver . . . at the middle of its posterior wall the foramen of Winslow connects it with the lesser sac . . . its apex is feebly shut off from the left anterior space.”

---

**Boundaries**

Superior — right lateral ligament and transverse fissure of the liver

Inferior — open to general peritoneal cavity

Anterior — inferior surface of liver with gall bladder

Posterior — upper part of the right kidney, lower part of and crus of diaphragm, common bile duct and duodenum

---

<i>Author/s</i>	<i>Nomenclature</i>
A	right posterior
B	right subhepatic with anterior and posterior divisions
C	right infrahepatic
D	right posterior
E	right posterior suprahepatic
F	right posterior
G	right infrahepatic
H	right posterior
I	right inferior
J	right posterior
K	right anterior subhepatic division
L	right infrahepatic
M	right posterior
N	right inferior
O	right inferior infrahepatic
P	right posterior
Q	right subhepatic
R	right lower
S	right inferior
T	right inferior infrahepatic
U	right posterior
W	right inferior
X	right subhepatic

---

TABLE 4

The upper posterior part of the Right Posterior Subphrenic Space of Barnard has been listed as a separate space by some authors

<i>Author/s</i>	<i>Nomenclature.</i>
A	<i>no mention</i>
B	<i>no mention</i>
C	<i>no mention</i>
D	<i>no mention</i>
E	right subhepatic
F	<i>no mention</i>
G	<i>no mention</i>
H	<i>no mention</i>
I	right posterior
J	<i>no mention</i>
K	right posterior
L	<i>no mention</i>
M	<i>no mention</i>
N	right posterior superior
O	right superior posterior suprahepatic
P	<i>no mention</i>
Q	posthepatic recess of right subhepatic
R	right upper posterior
S	right posterior superior
T	right posterior suprahepatic
U	<i>"there is scarcely any true recess up behind the posterior edge of the liver"</i>
V	right superior posterior
W	right posterosuperior
X	<i>no mention</i>

TABLE 5

### Left Anterior Subphrenic Space of Barnard

#### Boundaries

Superior — dome of the left diaphragm  
 Inferior — left lobe of the liver  
 Anterior — communicates with the general peritoneal cavity  
 Posterior — left lateral ligament of the liver  
 Medial — falciform ligament  
 Lateral — spleen

<i>Author/s</i>	<i>Nomenclature</i>
A	left anterior
B	left suprahepatic
C	left suprahepatic
D	left anterior
E	left suprahepatic
F	left anterior
G	left suprahepatic
H	left anterior
I	left superior
J	left anterior
K	<i>no mention</i>
L	left suprahepatic
M	left anterior
N	left superior
O	left superior suprahepatic
P	left anterior
Q	left subphrenic
R	left upper
S	left superior
T	left superior suprahepatic
U	left anterior
V	<i>no mention</i>
W	left superior
X	<i>no mention</i>

TABLE 6

The apical part of the Right Posterior Subphrenic Space of Barnard has been listed as a separate space by some authors

<i>Author/s</i>	<i>Nomenclature</i>
A	<i>no mention</i>
B	left subhepatic anterior division
C	left anterior infrahepatic
D	<i>no mention</i>
E	left anterior infrahepatic
F	left anterior
G	left anterior infrahepatic
H	<i>no mention</i>
I	left anterior inferior
J	<i>no mention</i>

K	left anterior
L	left anterior infrahepatic
M	left anterior
N	left anterior inferior
O	left inferior anterior infrahepatic
P	<i>no mention</i>
Q	diverticulum of left subphrenic
R	left lower anterior
S	left anterior inferior
T	left anterior inferior infrahepatic
U	<i>no mention</i>
V	left anterior
W	left anterior
X	left subhepatic

TABLE 7

**Left Posterior Subphrenic Space of Barnard**

"better known as the small sac of peritoneum"

<i>Author/s</i>	<i>Nomenclature</i>
A	left posterior
B	left subhepatic posterior division
C	left posterior infrahepatic
D	left posterior
E	left posterior infrahepatic
F	left posterior
G	left posterior infrahepatic
H	left posterior
I	left posterior inferior
J	left posterior
K	left posterior
L	left posterior infrahepatic
M	left posterior
N	left posterior inferior
O	left inferior posterior infrahepatic
P	left posterior
Q	left subhepatic
R	left lower posterior
S	left posterior inferior
T	left posterior inferior infrahepatic
U	left posterior
V	left posterior
W	left inferior
X	lesser sac

TABLE 8

The left lateral part of the Left Anterior Subphrenic Space of Barnard has been listed as a separate space by two authors and received passing mention from two others. Barnard himself indicates that the above space is partly perigastric and perisplenic.

Author/s	Nomenclature
A to K	no mention
L	mentions that the left subhepatic space is perihepatic, perigastric and <i>perisplenic</i>
M to Q	no mention
R	<i>perisplenic</i>
S and T	no mention
U	mentions the <i>perisplenic</i> space (corresponding to a downward extension of Barnard's left anterior space) in an 'alternative and more practical classification' to the one he has given in the first instance
V and W	no mention
X	<i>perisplenic</i>

Quite apart from the above findings, there was also seen a considerable difference of opinion amongst the authors consulted with respect to the importance of anatomical boundaries from the surgical point of view. Some tended to stress the anatomical aspect, others the surgical aspect of new limits produced by inflammatory adhesions and still others trod the middle path in assigning a reasonable balance of importance applied to both these considerations.

A few quotes concerning the above may perhaps be not out of place.

"Too much stress has perhaps been laid on the influence that anatomical boundaries in this region have on the site of these abscesses, for, in every case of intraperitoneal abscess part of the wall of the abscess is formed by inflammatory adhesions and not by anatomical structures" and later "intraperitoneal abscesses are to a greater extent<sup>1</sup> limited by anatomical boundaries" (Walker, 1950).

"It is not often that the boundaries of a subphrenic abscess correspond directly with the ligaments of the liver; more often the boundaries are formed by inflammatory adhesions" (Aird, 1957).

"Subphrenic abscesses are variously classified, but undoubtedly the best method depends upon their anatomical situation, being not only convenient but often indicating their aetiology, likely complications and best drainage route" (Brain, 1958).

<sup>1</sup> comparing them with extraperitoneal abscesses

"The anatomical descriptions of the subphrenic spaces are of academic rather than practical interest" (Hunt, 1948).

"A knowledge of the anatomy of this region is essential, both for a clear conception of the aetiology and pathology of subphrenic abscess and for an appreciation of the main factors in its treatment" (Maingot, 1961).

"A knowledge of the anatomy of this region is very necessary, both for a clear conception of the aetiology and pathology of subphrenic abscess, and for an appreciation of the essential facts of its treatment" (Cokkinis, 1936).

"Although exact anatomical boundaries are defined for these spaces, the extent of an abscess collection is determined by chronic or recent inflammatory adhesions as well as by anatomical structures" (Shepherd, 1960).

Returning to the subject of terminology, that the writer's 'dilemma' was not an isolated one is testified to by the fact that as far back as 1932, Nather and Oschner came across a similar predicament and stated that "on account of the confusing terms existing in the literature and the overlapping of the various spaces described, one of us<sup>2</sup> has worked out the following classification<sup>3</sup> which is described in detail in a previous publication<sup>4</sup>. According to this classification the various spaces represent the sites in the upper abdomen where a secondary abscess may develop and each space is purposely so named so that its name describes its location." It is the author's regret that the study of Nather's classification, which included a number of compound positional terms both of Latin and English origin, did not make possible a firmer grasp of the anatomical situation of the subphrenic spaces with any greater ease than through that of most others.

Mitchell (1940) was reiterative on this aspect of confusing terminology and stated his views with a force that was emphatic. In referring to Barnard's original classification he said that "this terminology, though it has the authority conferred by fairly long usage, is misleading and should be discarded." He went further and stated that "an understanding of the divisions of the supracolic space could be simplified if a uniform terminology was adopted" and closed his argument as follows; "these clumsy terms can be avoided by referring to the spaces lying immediately beneath the diaphragm as subphrenic, and those lying beneath the liver as subhepatic."

In view of the multiplicity of nomenclature, the clashes between positional terminology amongst many authors and the 'rejection' of certain potential spaces by many others, it seemed to the writer that here was a field for fruitful investigation.

Could there be a fundamental misconception to account for this considerable variation in descriptive surgical anatomy?

2 Nather.

3 Right upper anterior, right upper posterior, right lower; Left upper, left lower anterior, left lower posterior; Perisplenic.

4 Der prä- oder retroperitoneale Weg zum subphrenischen Abscess als typische Operation, (1922), *Arch. f. klin. Chir.*, 122, 24-99.

Was the fact that subphrenic infection is nowadays of such rare occurrence a factor responsible for the decline of adequate attention being paid to the anatomical aspect of the subject?

Or was the combination of these two possibilities answerable for a state of affairs where time honoured concepts were allowed to hold water without question, with the result that textbook descriptions of the potential intraperitoneal spaces below the diaphragm were mere transcriptions, without significant variation or with insignificant variation, from one manual to another?

It appeared to the author that the main problem of investigation of the intraperitoneal spaces below the diaphragm would revolve around the method to be adopted. Mitchell (1940) studied the spread of acute intraperitoneal effusions by experiments "under as natural conditions as possible" and based his conclusions with respect to the anatomy of the subphrenic spaces" on the writings of Morison, Box, Treves, Livingston and Lee McGregor, but mainly on the experiments to be cited, and on personal observations in the operating theatre and dissecting room." His "experiments were performed on stillborn infants, preferably fresh, or preserved with a watery solution containing 5 per cent carbolic, 5 per cent glycerin and 5 per cent alcohol, which prevented decomposition for the short period during which the specimens were kept; foetuses hardened with formalin were found to be useless." Cannulae were passed into the appropriate spaces through the abdominal wall or through an adjacent hollow viscus and fine barium emulsion was injected under low pressure and the progress of the barium was recorded radiographically by fluoroscopy and still films, one to three hours being necessary for each experiment.

Reference to the remaining authors cited in Table I were not productive with respect to the mode employed in the study of the location and boundaries of the subphrenic spaces with the exception of Shepherd (1960) who refers to the use of the surgeon's hand at laparotomy in the exploration of the extent of two spaces. Illustrations of the spaces in many of the references were either those of other authors or from standard texts of anatomy. The writer had perforce to conclude that the majority of the authors quoted had based their descriptions of the subphrenic spaces on findings that followed explorations of the preserved cadaver in the dissecting room.

Could this be a fourth factor responsible in part for the welter of nomenclature and differences in opinion on these spaces? It cannot be denied that the preservation of the tissues of the cadaver by formalin is influenced by the forces of gravity with respect to the exact anatomical relations of adjacent structures and that final hardening of tissues may occur in such a manner in the prone or supine body that the anatomical arrangements of organs, both solid and hollow, and particularly that of ligamentous attachments, within a closed cavity could therefore be at variance with that found in the living human body.

Anatomy that is of the greatest value to the surgeon is that which is live and it seemed to the writer that the only possible way of determining the true state of affairs would be

the appreciation of the situation in the living subject. As far as the peritoneal cavity was concerned the nearest and most feasible approximation to normal conditions for study would obtain in the operating theatre, provided that all observations were under similar situations for the avoidance and minimisation of errors.

#### MATERIAL AND METHOD

Studies were carried out in a series of male and female adolescent and adult surgical patients (with the exception of certain groups of cases to be mentioned subsequently) in whom the upper abdomen was freely laid open. The various intraperitoneal compartments below the diaphragm, above and below the liver and on the right and left side were manually explored, the hand being carefully swept backward, forward and sideways to determine the extent and boundaries of each potential space, the index finger being used in a similar manner for the exploration of spaces of small extent and depth.

With a view to approaching as uniform conditions as possible and elimination of significant errors, the studies were conducted under general anaesthesia in the phase of muscular relaxation provided by tubocurarine or gallamine, with the operation table in the neutral position with respect to the horizontal and sideways tilt, and with accessory attachments like mechanical bridges etc. likely to cause alterations of body contour, inoperative.

For obvious reasons, patients who fell into one or more of the categories mentioned below were excluded from this study.

- (a) generalised visceroptosis or localised visceroptosis including hepatoptosis
- (b) hepatic enlargement, localised or diffuse
- (c) gastric, splenic, pancreatic, renal and peritoneal lesions of a nature causing appreciable distortion of normal anatomy.
- (d) diaphragmatic abnormalities
- (e) intra-abdominal adhesions of previous operative or other origin

The argument may be brought forward that these intraperitoneal spaces are being subjected to study under artificial conditions—that of lowered intraperitoneal pressure and of abnormal muscular relaxation. It is difficult to visualise how these conditions could be circumvented and such a charge seems to be specious, since as far as the surgeon is concerned these conditions are likely to obtain in the majority of cases he would be dealing with, in the operative treatment of established infection in these spaces.

The patients who underwent final selection for this investigation were those admitted to the Surgical Unit of the University in the General Hospital, Colombo from January 1962 to December 1968 inclusive.

In all, with a final weeding out of a handful of patients who belonged to minority communities (Eurasian, Moor and Malay) in order to avoid any possible characteristics of racial peculiarity that might cloud the final analysis, a total of 273 adolescent and adult males and females came under investigation. The composite Table 9 shows the age, sex and racial incidence of the series that underwent study.

TABLE 9

*Sex, Age and Race Distribution of the Series Investigated.*

Total Number of Cases — 273		
<i>Sex</i>	<i>No. of Cases</i>	<i>%</i>
Males	183	67
Females	90	33
<i>Race</i>		
Sinhalese	195	71
Tamils	78	29
<i>Race and Sex</i>		
Sinhalese males	125	46
Sinhalese females	50	18
Tamil males	58	21
Tamil females	40	15
<i>Age Groups</i>		
10 — 19 years	10	4
20 — 29 "	35	13
30 — 39 "	83	31
40 — 49 "	77	28
50 — 59 "	40	14
60 — 70 "	28	10

## RESULTS AND EVALUATION

With respect to extent and boundaries of the different spaces, no significant differences were encountered as regards age, sex and the two main nationalities, each group of which had a reasonably fair representation in the subgroups of the series.

It is proposed to consider the extent, boundaries and other characteristics of each individual space in turn, in the total number of cases that were investigated.

*The right anterior space of Barnard*

This is the largest potential intraperitoneal space in the subphrenic group. With respect to the liver it was found to encompass the whole of the superior, anterior and lateral surfaces of the right lobe of the liver and a considerable part of the upper posterior surface too.

Except in the adolescent group of individuals and those of below average physical development, the exploration of the posterior limit of this space resulted in the disappearance of the gloved hand<sup>5</sup> from the operative field of vision, the free edge of the glove cuff in the majority of cases coming to 'rest' at or slightly above the anterior costal margin (Fig. 1). It was therefore obvious that this space was partly related to the greater part of the upper portion of the posterior surface of the right lobe of the liver, and therefore that the coronary and triangular ligaments of the liver were not attached to the superior surface of the liver on the right side. It is interesting to note that Barnard himself must have been of the view that these ligaments had a superior attachment to the right lobe of liver as evidenced by the diagram published in his original article (1908) showing the view of the upper surface of the liver exposed by removing the diaphragm and which is reproduced in Fig. 2. That many other authors held the same concept there is no doubt, since in Table 4 we find ten of them describing a second space above the liver and behind the right coronary and triangular ligaments, the clearest example being Handfield-Jones whose illustration of a sagittal section through the body to the right of the midline reproduced in Fig. 3 presents this concept most strikingly.

Harley (1949) was apparently the first to point out this error of surgical anatomy when he stated that "it is a common belief that the liver is suspended by its superior surface from the dome of the diaphragm through the medium of the coronary, triangular and falciform ligaments. . . . but in fact the coronary and triangular ligaments attach the posterior surface of the liver to the posterior abdominal wall, which is formed at this site by the diaphragm. . . . the liver is maintained in contact with the dome of the diaphragm not by ligamentous attachment, but by the attraction of mutually opposed surfaces separated by a capillary layer of fluid. If air is introduced into the peritoneal cavity, the liver falls away from the diaphragm, showing that the falciform ligament is a lax structure. It is as though the liver is hinged posteriorly upon the attachments of the coronary and triangular ligaments."

<sup>5</sup> the writer's hands take a standard No. 7 glove.

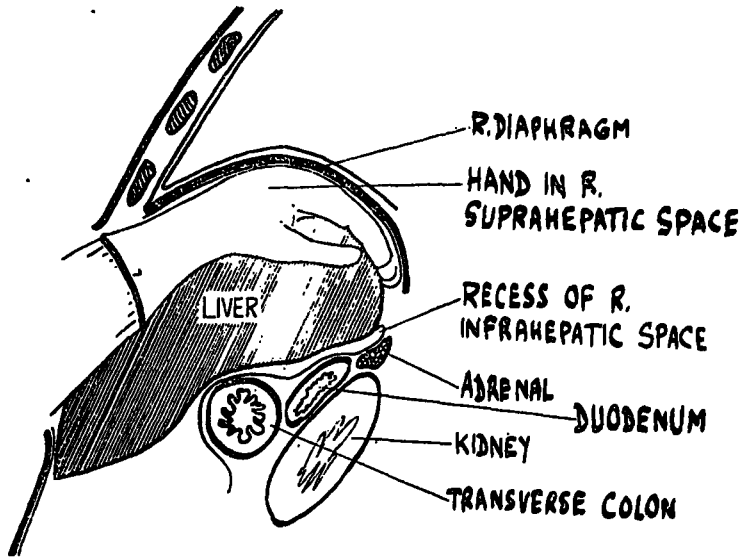


FIG. 1. Sagittal section through the abdomen to the right of the median plane. Semi-diagrammatic.

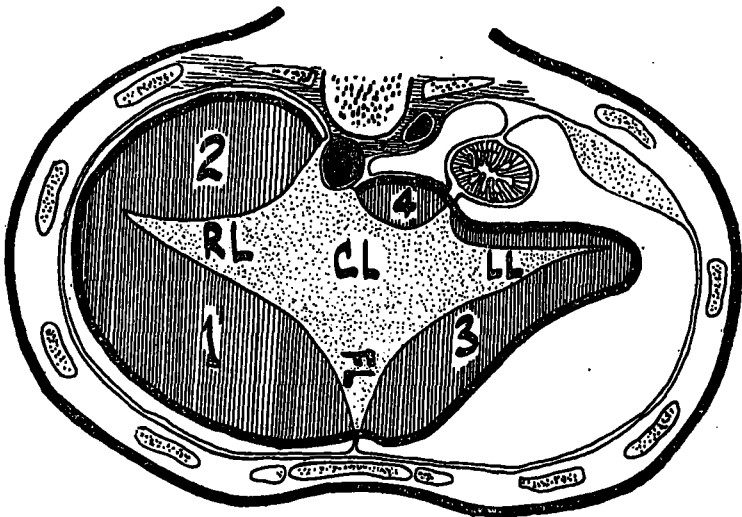


FIG. 2. Diagrammatic view of the upper surface of the liver exposed by removing the diaphragm. CL-Coronary ligament. FL-Falciform ligament. RL-Right lateral ligament. LL-Left lateral ligament. 1-Right anterior intraperitoneal space. 2-Right posterior intraperitoneal space. 3-Left anterior intraperitoneal space. 4-Left posterior intraperitoneal space or small sac or peritoneum. (Redrawn from Barnard's diagram, 1908, by kind permission of the Editor, British Medical Journal).

referred to textbooks of anatomy

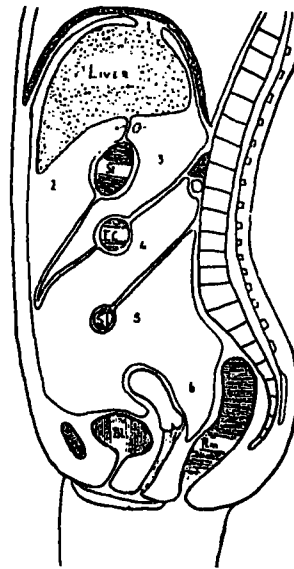


FIG. 282

Diagram illustrating some of the peritoneal compartments

1, is the bare area of the liver, 2, the anterior subhepatic compartment; 3, the lesser sac, the arrow indicating the foramen of Winslow; 4, the space between the transverse mesocolon and mesentery; 5, the space below the mesentery continuous with 6, pouch of Douglas.

FIG. 3. The coronary ligament of the liver (*Handfield-Jones, 1957; reproduced from "The Essentials of Modern Surgery", by kind permission of the publishers, Messrs. E & S Livingstone*)...

With respect to the anatomical boundaries of this space the findings were not at variance with those of other authors, viz.,

anterior — communicates with the supracolic compartment below the anterior liver edge

posterior — the superior layer of the right coronary and triangular ligaments

medial — the falciform ligament

lateral — communicates with the supracolic compartment round the right liver edge and the extremity of the right triangular ligament

superior — the right dome of the diaphragm and

inferior — the right lobe of the liver in its superior, anterior, lateral and posterior surfaces.

#### *The right posterior space of Barnard*

This space is roofed over by the inferior concave surface of the right lobe of the liver and bounded posteriorly by the reflection of the peritoneum between the posterior edge of the liver and the upper pole of the right kidney. Mitchell (1940) described a recess at

this point passing up behind the posterior edge of the liver—the posthepatic recess of his right subhepatic space. “This recess has been misrepresented by many workers, including Oschner and Graves (1933), Delario (1934), Oschner and DeBakey (1938), Faxon (1940), Clagett and Tinney (1944) and Thorek (1947), as the posterior superior space, which is supposed to lie above the liver” (Harley, 1957).

The assessment of the limits of this space was of particular interest in view of the above forthright statement of Harley and of its recognition by several others in addition to the authors mentioned by Harley-Nather (1922), McCorriston (1952), Berens, Howard and Dockerty (1953), Sawyer (1953), Handfield-Jones (1957), Wakeley (1960), Maingot (1961) and Farquharson (1962) as shown in Table 4.

Shepherd (1960) stated that “if at laparotomy the surgeon explores this area he will find that the hand cannot be passed upwards behind the posterior margin of the inferior surface of the liver.” This was the situation that was discovered in every single case of the 273 patients investigated in this series.

The situation was different when the index finger (and more so when the little finger) was employed to explore this area. In 193 (approximately 71%) of the total number of 273 cases a recess varying in depth up to 2 cm. was discovered.

From the surgeon's point of view this depth cannot be of any significance and the writer had to conclude as did Barnard (1908), Mitchell (1940) and Harley (1957) that there is only *one* space above the right lobe of the liver.

The boundaries of this space beneath the right lobe of the liver were :

above and in front — the right lobe of the liver

below and behind — the upper part of the right kidney, the right suprarenal gland, the second part of the duodenum, part of the head of the pancreas, the right colic flexure, the right extremity of the transverse colon and mesocolon

lateral (to the kidney) — the diaphragm and

medially — the gall bladder, the structures forming the epiploic foramen, the falciform ligament with the ligamentum terces.

#### *The left anterior space of Barnard*

The exploration of this space between the left lobe of the liver and the left leaf of the diaphragm was unproductive of findings significantly different from those of the authors who recognised it. Despite the fact that the left lobe of the liver is considerably smaller than the right and has contact with about half or less of the extent of the left cupola of the diaphragm, thus making this space correspondingly smaller than its right sided counterpart, it is a distinct space with distinct boundaries and quite worthy of recognition as a separate space, though ignored by three of the workers listed in Table 5.

The limits of this space are:

above — the left dome of the diaphragm

below — the left lobe of the liver

anteriorly — communicates with the general peritoneal cavity

posteriorly — the anterior layer of the left coronary and triangular ligaments.

medially — the falciform ligament separating it from the right anterior space and

laterally — passes backwards between the diaphragm and spleen.

*The apical part of the right posterior space of Barnard*

This space lies immediately below the left lobe of the liver and the hand passed into it between the liver and the stomach encounters the lesser omentum posteriorly and towards the midline. In attempting to determine the upper posterior limit of this space there was discovered a situation which ran contrary to the generally accepted view that the left triangular ligament is attached to the posterior margin of the left lobe of the liver. It was found that in 144 cases (approximately 53%) of the total of 273, that the tip of the finger could be insinuated to about the depth of 1.5 cm. above the posterior edge of the left lobe of the liver, thus giving a recess similar to that found in the right posterior space (and surgically equally insignificant) due to the attachment of the left triangular ligament to the posterior aspect of the superior surface of the left lobe of the liver rather than to its posterior margin.

In the attempt to determine the inferior limit of this space in its posterior part, the hand was found to slide over the posterior surface of the fundus of the stomach and further progress stopped by the tips of the fingers coming to rest at the barrier produced by the gastrophrenic ligament and the upper posterior attachment of the greater omentum to the stomach.

Barnard considered this space a part of his right posterior space—its apex, since he described the posterior space as a pyramidal one transversely disposed beneath the inferior surface of the liver and sloping upwards towards the left. On passing the hand in this space towards the right lobe of the liver a partition was encountered sufficiently regularly but not always to the same degree in every case—but a barrier that was easily appreciated in the majority of cases as to have it considered as the boundary of separation between the left and right portions of the space beneath the liver—namely, the lower free part and edge of the falciform ligament.

Inasmuch as the space above the left lobe of the liver was recognised by 21 authors (Table 5), it was surprising to find that the space below the left lobe which is at least of the same extent as the one above it, being refused recognition by three of them and mentioned by three others who did not accept the existence of a space above the left lobe! (Table 6)

The anatomic extent of this space was as follows :

above and in front — the left lobe of the liver

below and behind — the stomach and lesser omentum

- posteriorly and above — the posterior layer of the left coronary and left triangular ligaments
- posteriorly and below — the gastrophrenic ligament and the upper posterior part of the greater omentum over which there is communication with the space around the hilum of the spleen
- inferiorly — communicates with the general peritoneal cavity and with the space above the liver round the anterior edge of the left lobe of the liver
- medially — the lower part and edge of the falciform ligament under which there is communication with the right posterior space and
- laterally — passes round the fundus of the stomach towards the splenic hilum.

#### *The left posterior space of Barnard*

Exploration of this space was limited to 37 cases in this series as in this number only did the surgical procedure require opening up of the lesser sac. The findings were unproductive of any remarkable differences with respect to the extent and boundaries as quoted by other authors except for the demonstration of the well known surgical fact that the omental bursa rarely extended below the level of the transverse colon and that when it did so, it was only to an insignificant degree.

#### *The left lateral part of the left anterior space of Barnard*

As seen from Table 8, this area received a definite name as an individual space only from Nather (1922) and Walker (1950) -*perisplenic*- and a passing mention from Barnard (1908), Harley (1957) and Shepherd (1960), in that a left sided subphrenic abscess could be partly perisplenic as well.

The left cupola of the diaphragm has about an equal area of contact with the left lobe of the liver as with the spleen. If the space above the left lobe of the liver deserves a distinct name, there is no valid reason why the space related to the diaphragmatic surface of the spleen should be ignored, despite the fact that all the spaces on the left side, with the exception of the lesser sac, have free communication with each other as demonstrated by the ease with which the hand can be passed from above as well as below the left lobe of the liver into the space immediately subjacent to the left leaf of the diaphragm to sweep over the convex surface of the spleen as well as in the reverse direction from the space around the spleen into the spaces above and below the left lobe of the liver.

Admittedly the space below the left dome of the diaphragm is a large and complicated one with irregular communicating compartments but it would be easier to describe and name it in sections than to consider it as a complete individual space.

Barnard (1908) in describing the lateral extent of the left anterior space—the area in which an abscess would be perisplenic in position—mentions that this part of the fossa is continuous “below with the left lumbar pouch, which lies between the descending colon and the left loin.” A check of this statement in the actual series revealed that the exploring

hand does not have an easy passage from the space around the spleen downwards towards the left paracolic gutter. The phrenico-colic ligament is always present below the lower pole of the spleen to impede the hand from sliding smoothly into the "left lumbar pouch."

#### DISCUSSION

There is general agreement that the subphrenic region is that portion of the abdominal cavity which extends from the diaphragm above to the transverse colon and mesocolon below. Subdivision of this supracolic compartment is mainly due to the presence of the large mass of the liver, its ligamentous attachments and the reflexion of the peritoneum between the liver and the diaphragm, between the liver and adjacent viscera and between the diaphragm and adjacent viscera. Hence various potential intraperitoneal spaces (of interest to the surgeon from the point of view of accumulation of intraperitoneal effusions) are established.

The location of these spaces, their extent and their anatomical boundaries have been the subject of nomenclature designed to indicate their true position and relations, from various authors. That this nomenclature has lacked uniformity and has been at considerable variance with the production of more than a modicum of confusion has already been indicated together with the possible reasons for this state of affairs.

The results of a survey of these spaces in a considerable group of representative individuals have been productive of certain indubitable facts. If these findings could be woven into a nomenclature that from its very terminology makes it abundantly clear to the mind's eye the location of any individual space, then one would obviate the misleading, the confusion and the clumsiness of terminology 'complained' of by Oschner, Nather and Mitchell.

It seems to the writer that the *first* requirement of any attempt to reach such clarity with respect to the subphrenic spaces would be a minimal use of positional terms, and where such use is necessary only one such term and not a combination of terms would be highly desirable.

The *second* would concern the omission of the word subphrenic itself in the description of subdivisions of the subdiaphragmatic region, contrary to the advice of Mitchell who suggested the employment of this term for those spaces lying immediately below the diaphragm. Since there is general agreement that all the spaces should come under the parent or generic term of 'subphrenic' the repetition and re-employment of this term is best avoided lest it confuse the issue when the subdivisions are named.

The *third* and most important factor which would promote the mental visualisation of a given space would be the correlation of this space with the abdominal viscus which is its closest and major relation.

Taking these three essentials into due consideration, the nomenclature of the intraperitoneal subphrenic spaces could certainly be simplified in the following manner.

Since the main viscus that intrudes into the subphrenic space is the liver, the area obviously becomes compartmented into spaces above and below the liver. Thus there are *suprahepatic* and *infrahepatic* spaces—*infrahepatic*, rather than *subhepatic* since the converse or opposite of *supra*, the adverb of place (meaning above, over, on the top) is naturally the adverb *infra* (meaning beneath, on the under side) rather than *sub*, which is the ablative of place (meaning under, at the foot of) - Thomas (1935).

Further subdivision of the suprahepatic and infrahepatic spaces follow from the presence of the coronary and triangular ligaments of the liver, the suprahepatic compartment being divided into right and left portions by the main part of the falciform ligament, and the infrahepatic compartments compartment being similarly subdivided by the lower free border of the same ligament containing the ligamentum teres and the ligamentum venosum.

On the right side therefore, we have two spaces—RIGHT SUPRAHEPATIC (corresponding to the right anterior space of Barnard) and RIGHT INFRAHEPATIC (corresponding to the right posterior space of Barnard—the pouch of Rutherford Morison). Attention has been drawn to the fact that there is only *one* space above the right lobe of the liver and that the recess of the posterior part of the right infrahepatic space is insignificant in extent and not infrequently non-existent.

On the left side the suprahepatic and infrahepatic spaces are in free communication with each other and with the space around the spleen with the result that we have a left space which is large, irregular and complicated, separating the diaphragm from the left lobe of the liver, the stomach and the spleen with prolongations passing between the stomach and the liver and the stomach and the spleen. Notwithstanding the fact that the left lobe of the liver is considerably smaller than its right counterpart and in contact with about half or less of the left leaf of the diaphragm, more than half the area of the palpating hand slips into spaces both above and below the left lobe, making these spaces sufficiently individual and generous in extent to be worthy of separate designation. We therefore find a LEFT SUPRAHEPATIC space (corresponding to the left anterior space of Barnard) and a LEFT INFRAHEPATIC space (corresponding to the apical part of the right posterior space of Barnard).

Almost the full width and area of the hand is required to separate the spleen from the undersurface of the left cupola of the diaphragm lateral to the left lobe of the liver and hence there is no valid reason why this should not be called the PERISPLENIC space (corresponding to the left lateral part of the left anterior space of Barnard).

No controversy exists with respect to the presence, extent and boundaries of the omental bursa, which is a left infrahepatic space requiring no further qualification by any positional term since the use of the word LESSER SAC of peritoneum requires no additional embellishment or explanation in the description and location of this space as a clear anatomical entity.

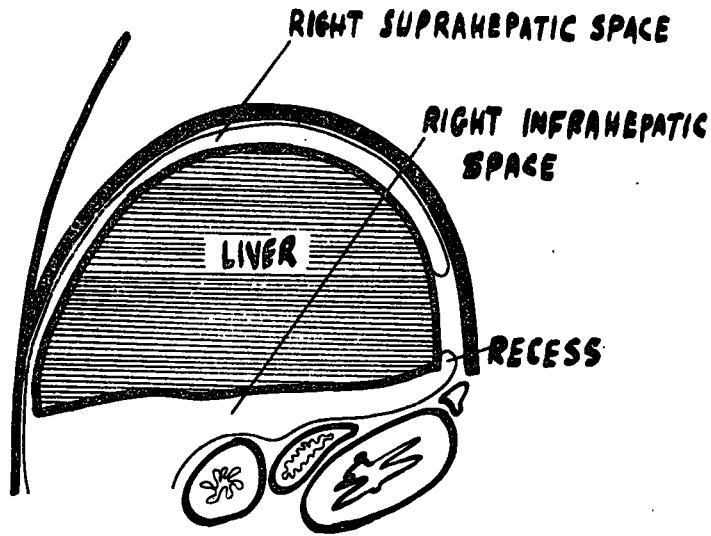


FIG. 4. Sagittal section through the abdomen to the right of the median plane. Diagrammatic.

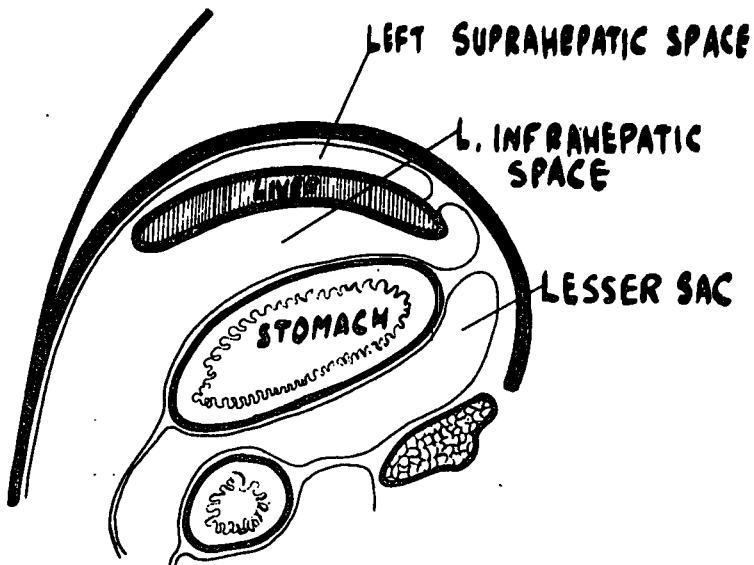


FIG. 5. Sagittal section through the abdomen to the left of the median plane. Diagrammatic.

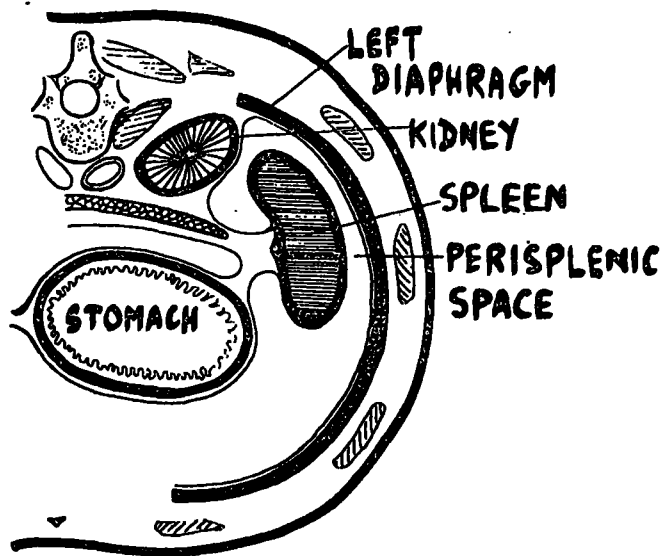


FIG. 6. Horizontal section through the upper abdomen, left side. Diagrammatic.

Figures 4, 5 and 6 are diagrammatic representations of sections of the body wherein the intraperitoneal subphrenic spaces are shown in conformity with the main findings of this investigation with respect to their location, close major relations and boundaries, and indicated with the names that have been suggested above.

#### SUMMARY

In view of the somewhat confusing terminology applied to the various potential intraperitoneal spaces which lie below the diaphragm, opportunity was taken during upper abdominal laparotomy of manually exploring these compartments in a series of selected adolescent and adult male and female surgical patients under 'standardised' conditions. The results of this survey with respect to the existence, location, extent and anatomical boundaries and relations of these spaces have been described and discussed with regard to the findings of other workers and in the light of establishment of a uniform terminology that is expressive, descriptive, practical and reasonably accurate.

The conclusions reached were that there are SIX potential intraperitoneal spaces in the subphrenic region of size worthy of separate nomenclature and the plea is made for the acceptance of the following terms as the most suitable, namely

*right suprahepatic*  
*right infrahepatic*  
*left suprahepatic*  
*left infrahepatic*  
*lesser sac and*  
*perisplenic.*

## ACKNOWLEDGEMENTS

It is a pleasure to mention my indebtedness to two of my academic colleagues of the University of Ceylon, Colombo - Professor F. L. W. Jayawardena of the Department of Anatomy and Professor S. R. Kottegoda of the Department of Pharmacology - for much helpful criticism and advice.

## REFERENCES

- BARNARD, H. L. (1908). Surgical Aspects of Subphrenic Abscess, *Br. med. J.*, 1, 371—377.  
COKKINIS, A. J. (1936). *Postgraduate Surgery*, ed. by Maingot, p. 1135, London, Pitman.  
HARLEY, H. R. S. (1949). Subphrenic Abscess, *Thorax*, 4, 1—30.  
HUNT, R. S. (1948). Subphrenic Abscess, *Br. J. Surg.*, 36, 185—197.  
NATHER, C. and OSCHNER, A. (1923). Retroperitoneal Operation for Subphrenic Abscess, *Surg. Gynec.&Obst.*, 37, 665—67  
THOMAS, M. I. (1935). *A New Latin-English English-Latin School Dictionary*, pp. 128, 240, 246, London, Cassell.