

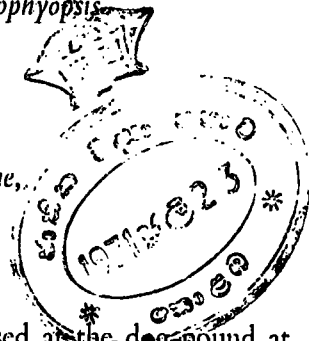**On Some Helminths of Dogs in Colombo and their bearing on Human infections,  
with a description of a New Trematode *Heterophyopsis*  
*yehi* Sp. nov. (Heterophyidae)**

by

A. S. DISSANAIKE

Department of Parasitology, Faculty of Medicine,  
University of Ceylon, Colombo

(With one Text Figure & two Plates)



BETWEEN May and July 1957 the small intestines of 29 dogs gased at the dog-pound at Magazine Road, were examined during a search for *Echinococcus* infection. A number of helminths were collected some of which have not hitherto been reported from the dog in this country. It is the purpose of this paper to record them and point out the part that helminths of dogs may play in human infections in Ceylon. A check list of helminth parasites of the dog from this part of the world is added.

The present collection comprises three species of trematodes, three species of cestodes, four species of nematodes and one acanthocephalan. Of these *Heterophyes heterophyes*, *Heterophyopsis yehi* sp. nov., *Echinochasmus perfoliatus*, *Taenia hydatigena* and *Ancylostoma ceylanicum* are recorded from the dog in Ceylon for the first time.

The table below summarises the main findings in the 29 dogs examined.

TREMATODA	
	Number of Dogs Positive
* <i>Heterophyes heterophyes</i>	7
* <i>Heterophyopsis yehi</i> sp. nov.	3
* <i>Echinochasmus perfoliatus</i>	1
CESTODA	
<i>Dipylidium caninum</i>	15
* <i>Taenia hydatigena</i>	1
<i>Echinococcus granulosus</i>	
NEMATODA	
<i>Toxocara canis</i>	14
<i>Ancylostoma caninum</i>	29
<i>Ancylostoma braziliense</i>	20
* <i>Ancylostoma ceylanicum</i>	7
ACANTHOCEPHALA	
One unidentified specimen	

(\*Denotes recorded in Ceylon for the first time).

### General Observations

The age of a dog was roughly assessed from its general appearance and dentition. The animals ranged from about one month to two years. The majority (21) were under 6 months and these were more heavily parasitised. About 50% of the dogs that harboured *Toxocara canis* were under six months and about 80% were probably under 2 months. Furthermore, every dog examined was infested with the hookworm *Ancylostoma caninum*, while *A. braziliense* and *A. ceylanicum* were less frequent. *Dipylidium caninum* was present in over 50% of the dogs.

### Trematoda

*Heterophyes heterophyes* (v. Siebold, 1852) Stiles and Hassal, 1900.

This a common intestinal parasite of man, the dog and the cat in Egypt, the Near East and the Far East. It has been reported from the dog in India (Maplestone and Bhaduri, 1940) but does not appear to parasitize man in that country, although the latter authors mention that two cases are on record from Calcutta. This is the first occasion on which this helminth has been found in Ceylon. The seven dogs that were infected had numerous worms in the small intestines and one of them harboured well over 150. They show the characteristic morphology of this species (Fig. A). They are extremely small flukes measuring 0.80 mm.—1.25 mm. in length and are easily missed in routine collections.

The life cycle of this worm involves a snail, which is the first intermediate host, and a second intermediate host which is a fresh water fish and invariably some species of the mullet (*Mugil* spp.) The metacercariae of this fluke are found under scales, in the gills, in the integument, in the fins and the tail and also embedded in the muscles of these fish. Man and other definitive host animals become infected by eating the infected fish either raw or improperly cooked, salted or pickled. It is not surprising, therefore, that they are common in man in those countries where people have the habit of eating such fish. It is unlikely therefore to become a serious problem at all in Ceylon, although we may meet with an occasional case perhaps in fresh-water fishmongers. It would be interesting and important, however, to search for the metacercariae in the fresh and brackish water fish in Ceylon and especially among the estuarine forms.

*Heterophyopsis yehi* sp. nov. (Fig. B. & C ; Text Fig. 1 and 2).

Only three specimens were recovered from three different dogs. They are small elongate flukes 1.91 mm. in length by 0.37 mm. in maximum breadth. The body in the anterior part is completely covered with spines which become scantier posteriorly.

The ventral sucker is situated anteriorly just behind the bifurcation of the gut. It is feebly developed and is more or less circular measuring 0.078 mm. by 0.080 mm. The oral sucker which is larger than the ventral sucker is subterminal and is 0.085 mm by 0.090 mm. A long slender prepharynx 0.147 mm. in length leads into a muscular ovoid pharynx which is 0.100 mm. by 0.080 mm. The bifurcation of the gut which is 0.350 mm. from the anterior tip of the worm follows soon after a very short oesophagus 0.040 mm. long. The intestinal caeca are straight slender tubes which probably extend to the posterior end, but are hidden by the coils of the uterus.

The testes lie in the posterior half of the worm in tandem position. The anterior testis is subspherical and is 0.110 mm. by 0.130 mm. while the posterior one is more globular and is 0.130 mm. in diameter lying with its posterior border 1.780 mm. from the posterior tip of the worm. The seminal vesicle is large and divided into two distinct portions by a narrow isthmus. The larger posterior portion is 0.290 mm. by 0.105 mm. and extends from the level of the anterior end of the ovary to the anterior part which lies immediately behind the genital sucker and is 0.080 mm. by 0.088 mm. From this leads the narrow prostatic part, and the ejaculatory duct passes round the left border of the genital sucker to open in the genital pore behind the female opening. The genital pore is surrounded by a disc shaped gonotyl which is armed with a circlet of numerous small rod-shaped spines. The genital sucker is small 0.050 mm. by 0.055 mm. and placed behind the ventral sucker a little to the right of the midline.

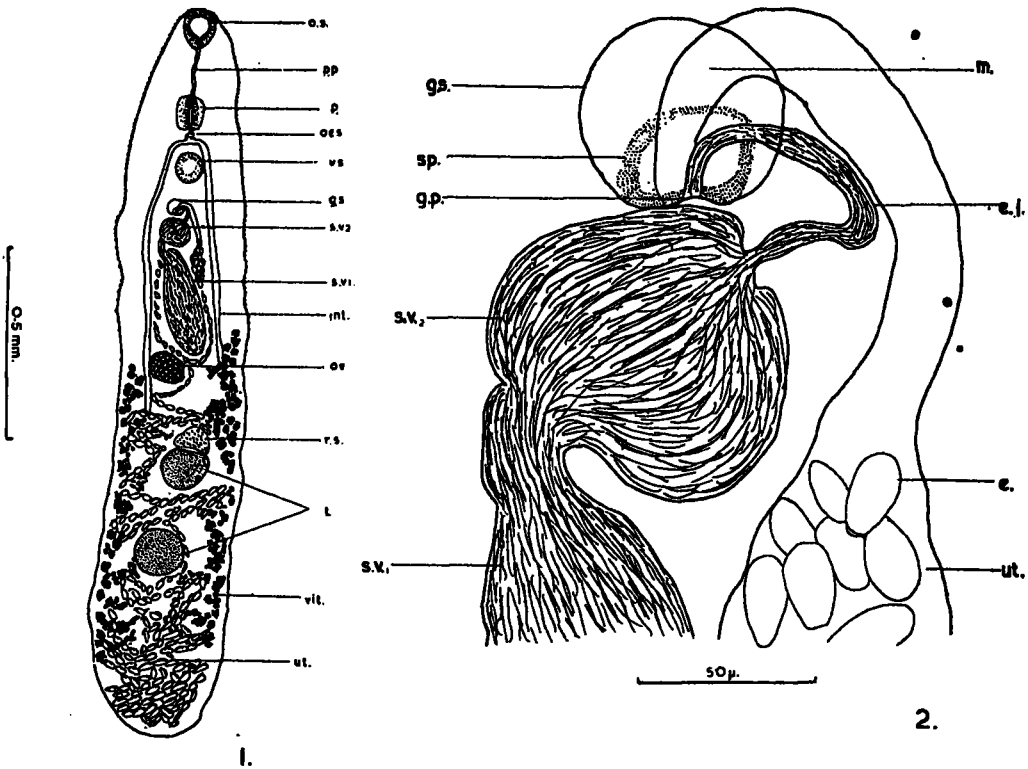


Figure 1—Ventral view of *Heterophyopsis yehi* sp. nov.

Figure 2—Genital sucker region of *H. yehi*.

Abbreviations used in Figures 1 and 2.

e. eggs; e.j. ejaculatory duct; g.s. genital sucker; g.p. genital pore; int. intestinal caecum; m. metratrem; o.s. oral sucker; oes. oesophagus; ov. ovary; p. pharynx; p.p. prepharynx; r.s. receptaculum seminis; s.v.1. seminal vesicle (post. part); s.v.2. seminal vesicle (ant. part); sp. spines; t. testes; ut. uterus; vit. vitellaria; v.s. ventral sucker.

The ovary lies to the right of the mid line just behind and to the right of the long portion of the seminal vesicle. It is ovoidal in shape and is 0.095 mm. by 0.078 mm. The receptaculum seminis is posterior to it and lies between it and the anterior testis which it caps. It measures 0.115 mm. by 0.065 mm. The coils of the uterus fill the entire body of the worm from the posterior extremity to the level of the ovary, from where they are seen on either side of the seminal vesicle, and the metraterm is seen winding round the left margin of the ejaculatory duct to open in the genital opening in front of the male opening. The uterus is filled with yellow operculated eggs which are thick shelled, oval and 22-26 $\mu$  by 10-15 $\mu$ . The vitellaria are arranged in coarse follicles extending from the level of the ovary to a distance well behind the posterior testis specially on the left side.

The writer proposes to name this species *Heterophyopsis yehi* after Dr. Yeh Liang Sheng to whom he owes a great deal in the systematics of helminths.

*Specific diagnosis* : Sub-family Heterophyinae Ciurea, 1924

*Heterophyopsis* Tubangui and Africa, 1938. Body elongate 1.91 mm. long by 0.37 mm. in maximum breadth. Anterior part of body covered with spines. Ventral sucker just behind bifurcation of gut 0.078 mm. by 0.080 mm. Oral sucker a little larger, subterminal and 0.085 mm. by 0.090 mm. Prepharynx long 0.147 mm. Pharynx ovoid, muscular 0.100 mm. by 0.080 mm. Oesophagus short 0.040 mm. Intestinal bifurcation 0.350 mm. from anterior extremity. Intestinal caeca long, slender. Testes in tandem position, anterior subspherical 0.110 mm. by 0.130 mm.; posterior testis spherical 0.130 mm. in diameter and 1.78 mm. from posterior extremity. Seminal vesicle long bipartite, posterior part 0.290 mm. by 0.105 mm, anterior part 0.080 mm. by 0.088 mm, just behind genital sucker. Ejaculatory duct winds round left margin of latter and opens in genital pore behind metraterm. Gonotyl disc-shaped with a circle of numerous small rodlike spines. Genital sucker 0.050 mm. by 0.055 mm., to right of mid line. Ovary ovoidal 0.095 mm. by 0.078 mm. to the right of mid line just behind posterior end of seminal vesicle. Receptaculum seminis capping anterior testis and 0.115 mm. by 0.065 mm. Uterine coils extend well into posterior end and up to level of ovary. Metraterm opens anterior to ejaculatory duct opening. Uterus full of eggs 22-26 $\mu$  by 10-15 $\mu$ , thick walled and with slight shoulder at anterior end. Vitellaria in coarse follicles extending from level of the ovary to well behind posterior testis.

Host : *Canis familiaris*.

Location : Small intestine.

Locality : • Colombo, Ceylon.

Type and paratype : In the Department of Parasitology, Faculty of Medicine, University of Ceylon, Colombo.

*Remarks :*

Africa and García (1935) described the first trematode of this genus from the small intestines of dogs in Manila, but named it *Heterophyes expectans*. Subsequently Tubangui and Africa (1938) placed it in a new genus naming it *Heterophyopsis expectans* on the following characters which clearly distinguish it from members of the genus *Heterophyes* :—the tandem position of the testes ; the location of the vitellaria in the lateral fields ; the position of the ventral sucker ; the extent of the uterus which passes posteriorly beyond the testes to the posterior end of the body ; the long S-shaped excretory bladder. They also included in the generic characters the disc shaped gonotyl that is armed with a circlet of serrated spines. It is evident from the description of the present species that it resembles this genus closely except that the gonotyl lacks serrated spines, the ovary is not median and the vitellaria extend beyond the posterior testis. It would thus appear that these latter characters are not of generic importance. The present species differs from the type species in the following characters :

1. The vitellaria extend well behind the posterior testis.
2. The gonotyl or genital sucker is armed with a circlet of spines which are, however, rod-like and not serrated.
3. The ovary is not median but to one side and is closer to the seminal vesicle than in *H. expectans*.
4. The ventral sucker is slightly smaller than the oral sucker.

There appear to be three species of this genus described so far :— *Heterophyopsis expectans*, *Heterophyopsis continua* (Syn. *Heterophyes continua* Onji et Nishio, 1916) and *Heterophyopsis continua major* (Yamaguti, 1939) (Syn. *Pseudoheterophyes continua major*, Yamaguti).

*Echinochasmus perfoliatus*. (v. Ratz, 1908). (Fig. D).

This worm was recovered only from one dog though six specimens were found. The life cycle is similar to that of the heterophyids and therefore it is not important from the human point of view in this country. The adult worm has been recovered from man in Japan where it has been acquired by eating raw fish (Tanabe, 1922).

### Cestoda

*Dipylidium caninum* (Linnaeus, 1758). (Figs. E and F).

This is the commonest cestode of the dog in Ceylon as well as in other countries. In spite of its frequency in dogs it is a rare parasite of man, where nearly all cases reported from different parts of the world are from children. This tape worm is acquired by the accidental swallowing of fleas infected with the cysticercoid stage and this apparently takes place more readily in children playing about with dogs. No case of infestation of man in this country is on record but the writer has been informed by Professor W. A. E. Karunaratne in a personal communication that he once came across the characteristic cucumber-seed shaped segments in the stool of a child many years ago, which he identified as *D. caninum*.

*Taenia hydatigena* Pallas, 1766 (Fig. G).

This cestode was encountered on a single occasion and is recorded, perhaps for the first time in Ceylon. Bhalerao (1935) cites this species as being reported from Ceylon by Southwell (1911 and 1914) who however gives no indication that he has definitely identified the worm. He (1911) merely states that 4 specimens of *Taenia serrata* were examined by him but all without heads.

*Echinococcus granulosus* (Batsch, 1786) (Fig. H).

Only a single gravid segment was found. It was 3.2 mm. by 0.6 mm. and contained about 175 eggs, although most of the eggs had been liberated. As the writer has stressed earlier (Dissanaike, 1957) the finding of even a single dog in the city infested with this tapeworm emphasises the importance of careful disposal of the offal of cattle and goats slaughtered in Colombo. Seneviratna (1955) had earlier reported the finding of positive dogs in the Kandy district. Although Southwell (1912) makes mention of this worm, there is no indication that he found it in Ceylon.

The writer has already pointed out the importance of the occurrence of *E. granulosus* in our dogs and has shown that the cattle in Ceylon harbour the larval form (hydatid cyst). He also indicated that the finding of a monkey infected with hydatid cysts meant that there is a sylvatic cycle going on in our jungles (Dissanaike, 1957, 1958). It need hardly be stressed therefore that man can get infected with hydatid cysts by accidentally swallowing the eggs of *E. granulosus* passed out in the faeces of infected dogs\*.

## Nematoda

It is being increasingly realised that certain infective nematode larvae of animals, particularly those of the dog and cat, on entering an abnormal host, like man, proceed to migrate either in the skin or in the viscera producing characteristic pathogenic reactions (Beaver et al. 1952, Beaver 1956, 1958, 1959, Karpinski et al. 1956, and Dent et al. 1956). The term "larva migrans" has been applied to these migratory larvae which never develop to the adult stage. *Toxocara canis* of the dog has specially been incriminated as the causal agent of "visceral larva migrans," while "cutaneous larva migrans" or "creeping eruption" is believed to be caused in humans by various infective hookworm larvae of animals. More recently the filarial worms of dogs and other animals are considered to be the aetiological agents in Tropical Pulmonary Eosinophilia or Eosinophilic Lung (Danaraj, 1956, Danaraj et al. 1957, 1959, Buckley, 1958).

\*Since writing this paper three more positive dogs were detected, at the dog pound, from a series of 28 dogs examined during September 1960. Two of these animals harboured well over a hundred mature worms.

*Toxocara canis* (Werner, 1786).

This ascarid of the dog is found commonly in younger dogs and the recent view regarding the mode of infection with this helminth is that it is prenatal. The young puppy gets infected while in the uterus of the mother and the larvae are believed to remain dormant in its lungs until after birth, and only then move on to the intestine to mature.

*T. canis* has been reported from the dog in Ceylon as early as 1904, for, as pointed out by Baylis (1936), Linstow's record of "*Ascaris mystax*" from a "young suckling puppy" probably refers to this species.

As Beaver et al. (1952) have shown the infective larvae containing eggs of *T. canis*, when swallowed by humans, particularly children, give rise to the now recognised eosinophilic reactions in the liver and other organs. The larvae do not reach the intestines to give rise to adults, but wander about in various organs and tissues causing symptoms in the process. In fact a number of neurological symptoms attributed in the past to *Ascaris lumbricoides* are now believed to be due to the larvae of *T. canis*, and perhaps of the other ascarids of animals accidentally infecting man. It is quite likely that the children in Ceylon who accidentally swallow infective eggs of *A. lumbricoides* from door-yard dust and polluted soils, pick up the infective eggs of *T. canis* at the same time. It would be useful and interesting therefore to examine the soil, house and door-yard dust in areas where the children are known to be heavily infested with roundworms in order to see how many of these polluted places contain the eggs of the dog and cat ascarids as well.

*Ancylostoma caninum* Ercolani, 1859 (Figs. I and L).

This is by far the commonest hookworm of dogs in most parts of the world and in the present series every dog was found to harbour this helminth. The three buccal teeth (Fig. I) and the characteristic arrangement of the bursal rays particularly the lateral rays are seen in Fig. L. In *A. caninum* these lateral rays are stout and are equally spaced.

*Ancylostoma braziliense* Gomesz and de Faria, 1901 (Figs. J and M).

*Ancylostoma ceylanicum* Looss, 1911 (Figs. K and N).

Of these two hookworms *A. braziliense* is the commoner one and until recently the two species were considered synonymous when Biocca (1951) reiterated the differences pointed out by earlier workers.

There are two characters by which these two species can readily be differentiated :—

1. Both have two pairs of ventral teeth in the buccal capsule but in general the smaller and inner tooth of *A. braziliense* is relatively less prominent than is the case with *A. ceylanicum* (Figs. J and K).
2. In the case of the lateral rays, the mediolateral ray and the postero-lateral ray are close together and widely separated from the externo-lateral ray in *A. ceylanicum*, while they are equally divergent in *A. braziliense* (Figs. M and N).

While *A. braziliense* has been recorded from the dog in Ceylon by Seneviratna (1955), this is the first occasion on which *A. ceylanicum* has been found from this host, although the original description of *A. ceylanicum* was from a civet cat from Ceylon.

From the human point of view the three species of hookworms of the dog have been recognised as causing different degrees of infection. Although it is known that *A. ceylanicum* can reach the adult stage in the intestine of man, *A. caninum* and *A. braziliense* can cause different types and degrees of "creeping eruption" while recently eosinophilic granulomata of the liver and other viscera have been shown to be caused by *A. caninum*.

### Acanthocephala

Only a single specimen was recovered and it was not possible from it to identify the species with certainty. Furthermore it may even have been a parasite of a fish that had been taken in by the dog.

### Discussion and conclusions

The helminth parasites of dogs in India have been named by Rao (1932), Acharya (1933), Southwell (1930), Bhalerao (1935) and Baylis (1936, 1939). Chandler (1925) and Maplestone and Bhaduri (1940) have in addition shown the importance of helminths of cats and dogs respectively in human infections. While it is clear that helminths of dogs can cause various degrees of infection and infestation in man, their importance in this respect has not hitherto been recognised in Ceylon, although from time to time the helminths of dogs have been reported by Linstow (1904, 1906), Crawford (1934), Southwell (1911, 1912, 1914, 1930), Baylis (1936, 1939), and Seneviratna (1955). The check list below gives the helminths so far recorded from the dog in Ceylon with the first authentic record in each case.

The human importance of the parasites found in the present series has already been pointed out above. Of the helminths reported by earlier workers, only *Diphyllbothrium latum* and the Dirofilarias *Dirofilaria immitis* and *D. repens* are of importance as potential parasites of man.

*D. latum* is unlikely to occur in man in Ceylon since it is acquired by eating uncooked or improperly cooked fresh water fish infected with the plerocercoid stage of the parasite. Although *D. immitis* has been reported by Linstow (1906) from a dog in Ceylon, Perera (1956) points out that Crawford was of the opinion that this dog was imported from China and was already infected when it arrived. This worm, in fact, has not been reported from here since. *D. repens* on the other hand, seems to be quite a common parasite in this country, and in view of the fact that the Dirofilarias and other filarial worms of animals are now believed to be the causal agents of Tropical Pulmonary Eosinophilia (Danaraj 1956, Danaraj et al. 1957, 1959, Buckley 1958) it must be treated as the chief agent of this syndrome in Ceylon. Crawford (1934) estimated the incidence of microfilariae in dogs at 30%, while McGaughey (1952) and Perera (1956) have shown a high incidence in the Colombo and Kandy districts respectively. The writer estimates that in the Dehiwela-Mt. Lavinia area the microfilaria rate is about 60%. Serological studies similar to those carried out in Malaya are therefore indicated to find out the exact relationship between *D. repens* and this syndrome.

It is being increasingly realised that the dog is the chief reservoir of many zoonoses of man and this is particularly true of the helminths of the dog in Ceylon. The writer is therefore inclined to agree with Garnham (1958) that "if animals are to be exterminated, then it looks as though the dog should be a victim."

### Summary

The following helminths have been recorded from the dog in Ceylon for the first time:—*Heterophyes heterophyes*, *Heterophyopsis yehi*, sp. nov., *Echinochasmus perfoliatus*, *Taenia hydatigena* and *Ancylostoma ceylanicum*.

The role of these and other helminths reported from the dog in Ceylon in respect to human infection has been discussed.

A check list of helminth parasites of dogs in Ceylon has been added.

### Acknowledgements

The writer is grateful to Dr. D. W. Amarasinghe, Chief Municipal Veterinary Surgeon, Colombo and to Mr. M. D. Daniel, Officer-in-Charge of the Dog pound at the time of the investigations, for providing facilities to collect the material; to Dr. Yeh Liang Sheng for his invaluable help and suggestions; and to Mr. R. Surendranathan for the photomicrographs.

### Check List of Helminths of Dogs in Ceylon

#### TREMATODA

Heterophyidae Odhner, 1914.

*Heterophyes* Cobbold, 1886.

*Heterophyes heterophyes* (v. Siebold, 1852) Stiles and Hassal, 1900

.....Dissanaïke, present paper.

*Heterophyopsis* Tubanguï et Africa, 1938.

*Heterophyopsis yehi* sp. nov.

.....Dissanaïke, present paper.

Echinostomatidae Poche, 1926.

*Echinochasmus* Dietz, 1909.

*Echinochasmus perfoliatus* (v. Ratz, 1908)

.....Dissanaïke, present paper.

#### CESTODA

Diphyllobothriidae

*Diphyllobothrium* Cobbold, 1858.

*Diphyllobothrium latum* (Linnaeus, 1758)

.....Senewiratna (1955).

Mesocestoididae Perrier, 1897.

*Mesocestoides* Vaillant, 1863.

*Mesocestoides lineatus* (Goeze, 1782) Railliet, 1893

.....Senewiratna (1955).

## Taeniidae Ludwig, 1886.

*Taenia* Linnaeus, 1758 sensu strictu*Taenia hydatigena* Pallas, 1766

..... Dissanaïke, present paper.

*Echinococcus* Rudolphi, 1801.*Echinococcus granulosus* (Batsch, 1786)

..... Seneviratna (1955).

## Dilepididae Railliet and Henry, 1909.

*Dipylidium* Leuckart, 1863.*Dipylidium caninum* (Linnaeus, 1758)

..... von Linstow (1906).

## NEMATODA

## Ascarididae Baird, 1853.

*Toxocara* Stiles, 1905.*Toxocara canis* (Werner, 1782)

..... von Linstow (1904).

*Toxascaris* Leiper, 1907.*Toxascaris leonina* (von Linstow, 1902)

..... Seneviratna (1955).

## Ancylostomidae Looss, 1905.

*Ancylostoma* Dubini, 1840.*Ancylostoma caninum* Ercolani, 1859

..... von Linstow (1906).

*Ancylostoma braziliense* Gomez & de Faria, 1901

..... Seneviratna (1955).

*Ancylostoma ceylanicum* Looss, 1911

..... Dissanaïke, present paper.

## Filariidae (Cobbold, 1864) Claus, 1885.

*Dirofilaria* Railliet and Henry, 1911.*Dirofilaria immitis* (Leidy, 1856)

..... von Linstow (1906).

*Dirofilaria repens* Railliet and Henry, 1911.

..... Crawford (1934).

## Spiruridae Cerly, 1885.

*Spirocera* Railliet and Henry, 1911.*Spirocera lupi* (Rudolphi, 1809).

..... von Linstow (1906).

## ACANTHOCEPHALA

Unidentified specimen

..... Dissanaïke, present paper.

## REFERENCES

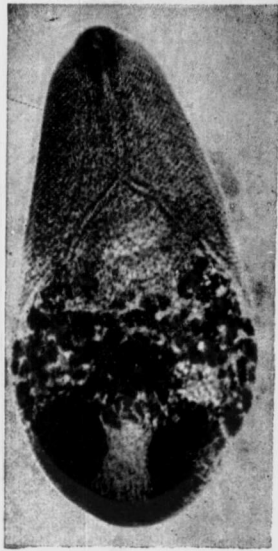- ACHARYA, S. K. (1933). Incidence of Helminth Parasites in Pariah Dogs. *Ind. vet. J.* 9, 210.
- AFRICA, C. M. & GARCIA, E. Y. (1935). Heterophyid Trematodes of Man and Dog in the Philippines with a Description of three new species. *Philipp. J. Sci.* 57, 253—267.
- BAYLIS, H. A. (1936). Fauna of British India, Nematoda, 1. Taylor and Francis, London.
- (1939). Fauna of British India, Nematoda 2, Taylor and Francis, London.

- BEAVER, P. C. (1956). Larva Migrans, Parasitological Reviews, *Exp. Parasit.* 6, 578—621.  
 (1958). Animal Parasites and Human Discases. *Pediatrics.* 22, 380—384.  
 (1959). Visceral and Cutaneous Larva Migrans. *Public Health Reports.* 74, 328—332.
- BEAVER, P. C., SNYDER, H., CARRERA, G., DENT, J. AND LAFFERTY, J. (1952). Chronic eosinophilia due to visceral larva migrans. Report of three cases. *Pediatrics.* 9, 7—19.
- BHALERAO, G. D. (1935)—Helminth Parasites of the Domesticated Animals in India. The Imperial Council of Agricultural Research. Scientific Monograph 6, Delhi.
- BIOCCA, E. (1951). On *Ancylostoma braziliense* (de Faria, 1910) and its Morphological Differentiation from *A. ceylanicum* (Looss, 1911). *J. Helminth.* 25, 1—10.
- BUCKLEY, J. J. C. (1958). Tropical Pulmonary Eosinophilia in relation to filarial infections (*Wuchereria* spp.) of animals. *Trans. R. Soc. trop. Med. Hyg.* 52, 335—336.
- CHANDLER, A. C. (1925). The helminth parasites of Cats in Calcutta and the relation of cats to human helminthic infections. *Ind. J. Med. Res.* 13, 213—228.
- CRAWFORD, M. (1934). Administration Report of the Government Veterinary Surgeon for 1933. Ceylon Government Press.
- DANARAJ, T. J. (1956). The treatment of eosinophilic lung (tropical eosinophilia) with Hetrazan (A preliminary Report) *Proc. Alumni. Ass. Malaya.* 9, 172—187.
- DANARAJ, T. J., DA SILVA, L. S., AND SCHACHER, J. F. (1957). The filarial complement fixation test in Eosinophilic lung (tropical eosinophilia) A preliminary report. *Ibid.*, 10, 109—116.  
 (1959)—The serological diagnosis of eosinophilic lung (tropical eosinophilia) and its etiological implications. *Amer. J. trop. Med. Hyg.* 8, 151—159.
- DENT, J. H., NICHOLAS, R. L., BEAVER, P. C., CARRERA, G. M., AND STAGGERS, R. J. (1956). Visceral larva migrans -with a case report. *Amer. J. Path.* 32, 777—803.
- DISSANAIKE, A. S. (1957). Some Preliminary observations on Echinococcus infection in local cattle and dogs. *Cey. Med. J.* 4, 69—75.  
 (1958). On Hydatid infection in a Ceylon Toque Monkey, *Macaca sinica*. *Cey. vet. J.* 7, 33—35.
- GARNHAM, P. C. C. (1958). Zoonoses or Infections Common to man and Animals. *J. Trop. Med. (Hyg.)*. 61, 92—94.
- KARPINSKI, F. E., EVERTS-SUARZ, E. A. AND SAWITZ, W. G. (1956). Larval granulomatosis (Visceral larva migrans). *Amer. J. Dis. Child.* 92, 34—40.
- LINSTOW, O. VON. (1904). Nematoda in the collection of the Colombo Museum. *Spolia zeylan.* 1, 91—104.  
 (1906). Helminthes from the Collection of the Colombo Museum. *Ibid.*, 3, 163—188.
- MAPLESTONE, P. A. AND BHADURI, N. V. (1940). The Helminth Parasites of Dogs in Calcutta and their bearing on Human Parasitology. *Ind. J. med. Res.* 28, 595—604.
- MCGAUGHEY, C. A. (1952). Filariæmia of Dogs in Ceylon. Treatment with diethyl carbamazinc. *Vet. Rec.* 64, 66
- PERERA, S. J. E. (1956). Preliminary survey of the incidence of filariasis in dogs in Kandy District. *Cey. vet. J.* 4, 22—24.
- RAO, M. A. N. AND PARAMESWARI AYYAR, L. S. (1932) *Heterophyes* species from dogs in Madras. *Ind. Vet. J.* 8, 251—252.
- SENEVIRATNA, P. (1955). A Check List of Helminths in the Department of Veterinary Pathology, University of Ceylon, Peradeniya. *Cey. vet. J.* 3, 32—37.
- SOUTHWELL, T. (1911). Some remarks on the occurrence of Cestodes in Ceylon. *Spolia zeylan.* 7, 194—196.  
 (1912). A description of Ten New species of Cestode parasites from marine fishes of Ceylon with notes on other Cestodes from the same region. *Rep. Ceylon Mar. biol. Lab.*, 1, 259—278.  
 (1914). A short account of our present knowledge of the Cestode Fauna of British India and Ceylon. *J. Asiat. Soc. Beng.* 10, 139—145.  
 (1930). Fauna of British India. Cestoda vols. 1 and 2. Taylor and Francis Ltd., London.
- TANABE, H. (1922). *Echinocasmus perfoliatus* (Ratz) found in Japan. *J. Okayama med. Ass.* 387, 1—20. (Cited by Faust and Russel in Craig and Faust's Clinical Parasitology. 6th Edition, London).
- TUBANGUI, M. A. AND AFRICA, C. A. (1938). The systematic position of some Trematodes reported from the Philippines. *Philipp. J. Sci.* 67, 117—127.
- YAMAGUTI, S. (1939). Studies on the Helminth Fauna of Japan. Pt. 25. Trematodes of Birds. *Jap. J. Zool.* 8, 129—162.

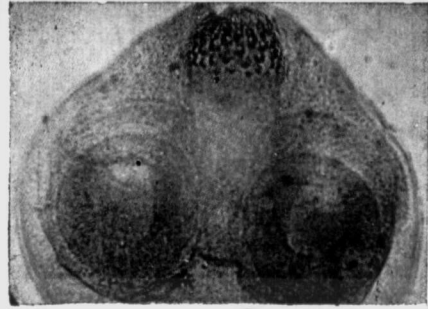
## EXPLANATION OF FIGURES

- Figure A—Ventral view of *Heterophyes heterophyes* (x81).  
Figure B—Dorsal view of *Heterophyopsis yehi* sp. nov. (x28).  
Figure C—Ventral view of *Heterophyopsis yehi* sp. nov. (x28).  
Figure D—Ventral view of anterior portion of *Echinochasmus perfoliatus* (x70).  
Figure E—Scolex of *Dipylidium caninum* (x140).  
Figure F—Segment of *D. caninum* (x287).  
Figure G—Scolex of *Taenia hydatigena* (x32).  
Figure H—Gravid segment of *Echinococcus granulosus* (x125).  
Figure I—Dorsal view of buccal capsule of *Ancylostoma caninum* (x140).  
Figure J—Dorsal view of buccal capsule of *A. braziliense* (x140).  
Figure K—Dorsal view of buccal capsule of *A. ceylanicum* (x140).  
Figure L—Lateral view of bursa of *A. caninum* (x140).  
Figure M—Lateral view of bursa of *A. braziliense* (x140).  
Figure N—Lateral view of bursa of *A. ceylanicum* (x140).

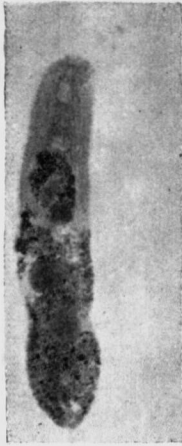(M.S. received 3-12-60)



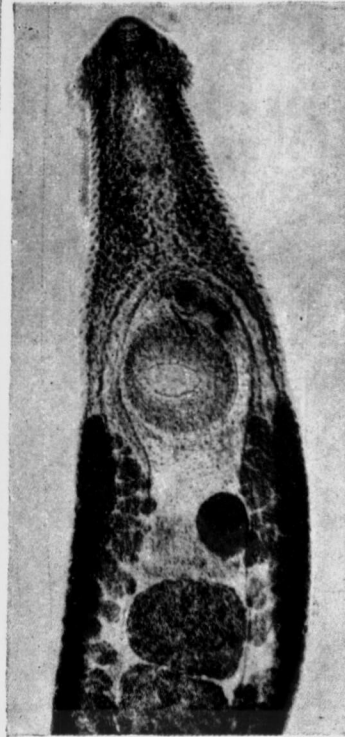
A



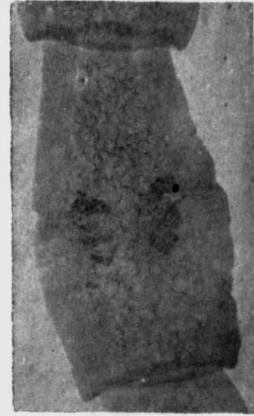E



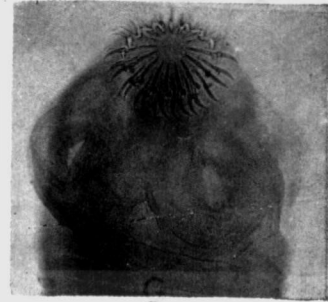
B



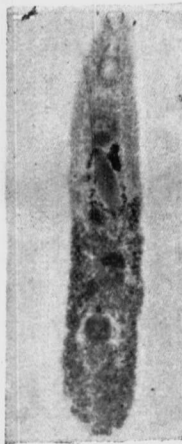D



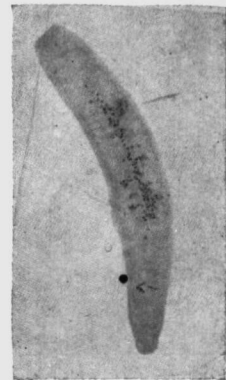F



G

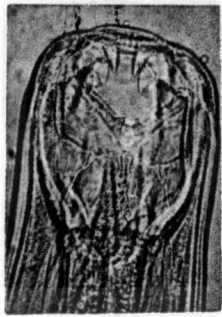

C

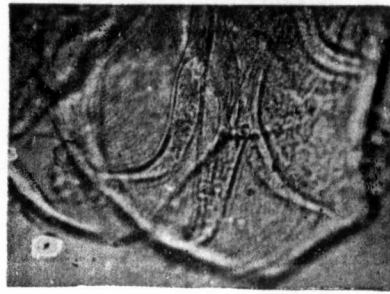

H

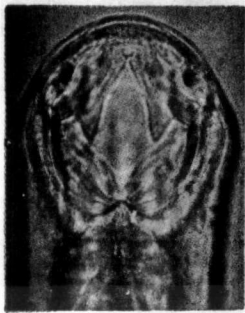
FIG. I



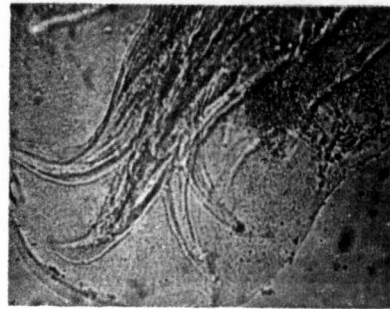
I



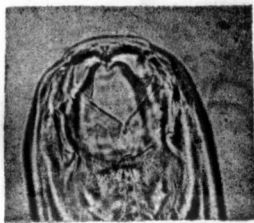
L



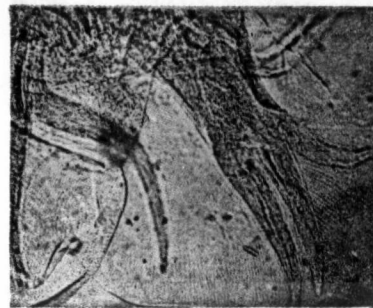J



M



K



N

FIG. 2