

Images in Medicine

## Neurofibromatosis - 2

SAMAN B GUNATILAKE\*

*Journal of the Ceylon College of Physicians*, 1991, 24, 57-59

The neurofibromatoses are autosomal dominant genetic disorders that primarily affect cell growth of neural tissues, and consist of two distinct disorders, now named as neurofibromatosis type 1 also known as Von Recklinghausen's disease and neurofibromatosis type 2. The defective gene for neurofibromatosis type 1 (NF-1) has been located to the chromosome 17 and for neurofibromatosis type 2 (NF-2) to chromosome 22<sup>1</sup>. Type 1 is about ten times commoner than type 2.

**The patient** — A 33 year old male presented with headache, deafness and tinnitus. Deafness was more on the right side and was of sensorineural type. He had bilateral cerebellar signs and the gait was ataxic. He also had bilateral papilloedema.

**Investigations** — Audiometry showed bilateral nerve deafness, the X-rays of the skull, Towne's view and per-orbital views showed widening of the internal auditory meatus on the left side. A cranial computerised tomographic scan showed bilateral large acoustic neuromata (figure).

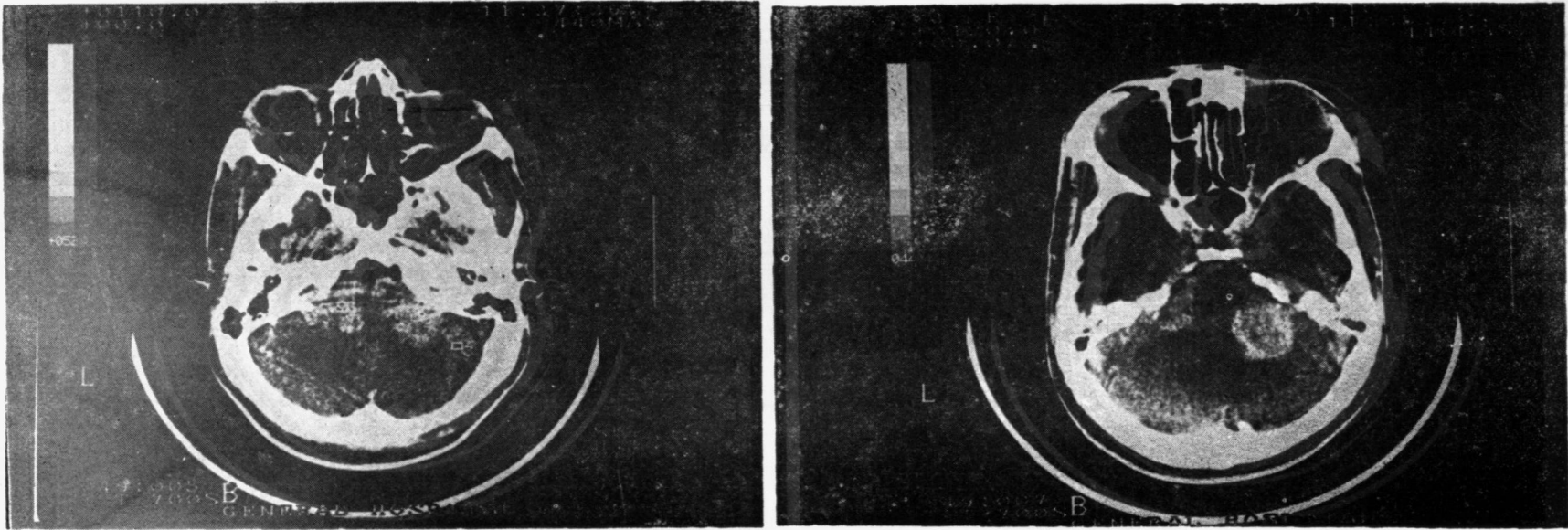
**Comment** — It is important to distinguish NF-2 from NF-1, because the genetic basis and the natural history are distinct in the two disorders. It is also

important to identify the sporadic unilateral acoustic neuroma from NF-2. The solitary acoustic neuroma tends to develop later in life, is not inherited and is unilateral. Bilateral acoustic neuromata are not seen in patients with NF-1<sup>2</sup>. The hallmark of NF-2 is bilateral acoustic neuromata. Criteria for making a diagnosis of these two forms of neurofibromatoses are shown in table 1<sup>3</sup>. Lisch nodules which are melanocytic hamartomas that appear as well defined, rounded elevations from the surface of the iris have been found to be specific for NF-1 and recent reports suggest that all patients with NF-1 who are above 21 years will have these lesions<sup>4</sup>.

NF-2 should be suspected in the following situations: 1) Parent, sibling or child is affected with NF-2. 2) Unilateral acoustic neuroma with onset of symptoms before 30 years of age. 3) A child with meningeal or Schwann cell tumour. 4) Person of any age with multiple nervous system tumours not attributable to another disorder. 5) An adult who has no family history of NF-1 and has one or more café au lait spots and no Lisch nodules.

Persons in these categories require a thorough skin examination for café au lait spots, an eye examination for Lisch nodules and an audiologic study with brain stem auditory evoked responses.

\* Consultant Neurologist, General Hospital (Teaching), Galle.



**Fig. 1** CT scan of the brain (contrast enhanced) showing bilateral acoustic neuromas

**Table I**  
**Criteria for Diagnosis of the Neurofibromatoses**

**Neurofibromatoses type 1**

Neurofibromatosis 1 may be diagnosed when two or more of the following are present :

1. Six or more cafe au lait spots whose greatest diameter is more than 5 mm in prepubertal patients and more than 15 mm in postpubertal patients
2. Two or more neurofibromas of any type, or one plexiform neurofibroma
3. Freckling in the axillary or inguinal region
4. Optic glioma
5. Two or more Lisch nodules
6. A distinctive osseous lesion such as sphenoid dysplasia or thinning of long bone cortex, with or without pseudoarthrosis
7. A parent or sibling, or child with neurofibromatosis 1

**Neurofibromatosis type 2**

Neurofibromatosis 2 may be diagnosed when one of the following is present :

1. Bilateral eighth nerve masses seen with appropriate imaging techniques
2. A parent, sibling or child with neurofibromatosis 2 and either unilateral eighth nerve mass or any two of the following: neurofibroma, meningioma, glioma, schwannoma, or juvenile posterior subcapsular lenticular opacity

**REFERENCES**

1. National Institute of Health Consensus Development Conference. Neurofibromatosis. Conference statement. *Archives of Neurology* 1988; 45: 575-578.
2. Eldridge R. Central Neurofibromatosis with bilateral acoustic neuromata. *Advances in Neurology* 1981; 29: 57-65.
3. Martuza R L, Eldridge R. Neurofibromatosis 2. *N Engl J Med* 1988; 318: 684-688.
4. Lubs M L E, Bauer M S, Formas M E, Djokic B. Lisch nodules in Neurofibromatosis type 1. *N Engl J Med* 1991; 324: 1264-1266.