

***Bertiella studeri*: a case of human infection**

N. D. Karunaweera^{1*}, R. L. Ihalamulla¹, H. K. Wickramathanthri¹ and A. Lamahewage²

The Ceylon Journal of Medical Science 2001; 44: 23-24

Summary

A case of human infection with *Bertiella studeri*, a tapeworm of monkeys is reported. Interestingly this is the 3rd case reported from Dikwella, in southern Sri Lanka, an area densely populated by monkeys and the 4th case from Sri Lanka.

Key words: *Bertiella studeri*, human infection, Sri Lanka

Introduction

Bertiella studeri is a tapeworm parasite which inhabits the small intestine. Monkeys are the natural hosts of the parasite. Intermediate hosts of *B. studeri* are certain species of oribatid mites which are found in soil. Human infection can occur as a result of accidental ingestion of these infected mites, containing the cystercercoid stage of the worm. It is considered a parasite that can affect children due to their habit of picking up objects from contaminated soil (reviewed in 1). The first case of human infection in Sri Lanka was reported in 1976 (2) and two cases have been reported since then (3).

Case Report

A 10½ year-old girl, from Dikwella presented at a private consultation chamber in Colombo with a history of bleeding per rectum on and off for six months and frequent passage of white, flat, motile, segmented worms with stools. Previously she has been treated at the General Hospital Matara with mebendazole and vitamins without any response. She was then admitted to Lady Ridgeway Hospital, Colombo where sigmoidoscopy and biopsy were done. These investigations revealed inflammatory changes in the mucosa.

Samples of stools together with segments of the worm were sent to the Department of the Parasitology, Faculty of Medicine, Colombo. Stools culture report was negative for pathogenic organisms.

Parasitological Diagnosis

The segments of the worm were broader (1-1.5 cm) than long (1-1.5 mm). They were thick and fleshy, packed together in a batch of about 10 segments. A few were crushed and examined for eggs which had a characteristic appearance. The rest stained with aceto-carmin. The morphology of the eggs with the characteristic 'pyriform apparatus' (Fig. 1) and the irregularly alternating genital pores in the segments (Fig. 2) confirmed the identification of the worm as *B.studeri*. Microscopic examination of the stool smear showed numerous red cells and pus cells. No parasitic cysts or ova were seen.

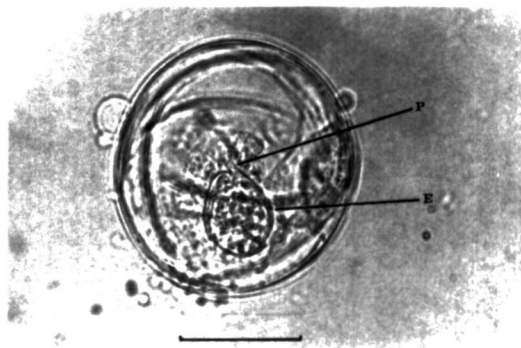


Fig 1: Egg of *B.studeri* showing the embryophore (E) and the characteristic "pyriform apparatus" (P) (Bar = 30 µm)

1. Department of Parasitology, Faculty of Medicine, University of Colombo, Colombo 8, Sri Lanka.

2. Lady Ridgeway Hospital, Colombo 8, Sri Lanka.

* Author for correspondence

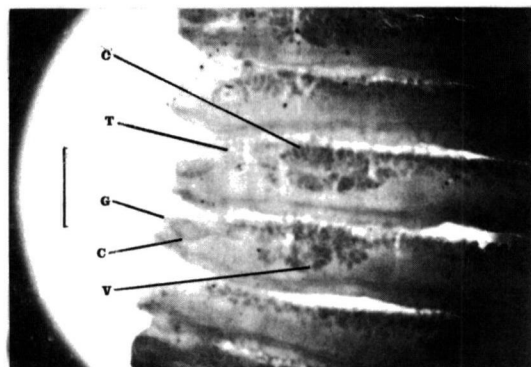


Fig. 2: Mature segments (one half only) showing irregularly alternating genital pores and other reproductive structures testes (T), ovary (O), vitelline gland (V), genital pore (G), cirrus pouch (C) (Bar = 1mm).

Treatment and follow up

The child was treated with oral niclosamide (2g as a single dose) immediately followed by a suppository (bisacodyl). After 2 hours the dead worm with proximal segments was passed. The samples were sent to the Department of Parasitology for identification. The scolex could not be seen. Parents were advised to report if segments reappear in stools especially during the first 3 months following treatment.

Discussion

Human infection of *Bertiella studeri* is reported from Dikwella (situated in southern part of the country). Interestingly two similar cases have been reported in the past from the same village. This area is densely populated with monkeys, which often enter house premises in search of home grown fruits. Both the toque monkey *Macaca sinica* and the grey langur *Presbytis entellus thersites* (= *Semnopithecus entellus*) the two most

likely reservoir hosts of this parasite live in this region. This may explain the unusual number of human infections reported from the area.

Although the scolex was not detected, it is likely that it was shed following treatment, as the patient did not report reappearance of segments up to the time the manuscript was written (5 months after treatment). Bleeding per rectum as experienced by this patient is not a known clinical manifestation of *B.studeri* infection as it is a parasite that inhabits the small intestine. The symptom persisted in spite of effective treatment for *B.studeri* infection which indicate a different aetiology. Presently, further investigations are being carried out to determine the exact cause of this symptom.

Acknowledgements

We thank Mr. C. P. Gamage for handling the samples, Professor A. S. Dissanaiké for his valuable advice and Mr. R. A. A. N. Ranawaka of the Photographic Unit, Faculty of Medicine, University of Colombo for assistance in photomicrography.

References

1. Dissanaiké AS. Uncommonly reported parasitic infections of childhood and parasites of the future. *Ceylon Journal of Child Health* 1995; 24:1-8
2. Edirisinghe JS, Cumararajan SM. The first record of *Bertiella studeri* infection in a child from Sri Lanka. *Ceylon Medical Journal* 1976; 22:137-140.
3. Weerasooriya MV, De Silva DDS, Mendis DH. *Bertiella studeri* infection in children - report of cases. Proceedings of the 48th Annual Session of the Galle Clinical Society, 26th - 27th August 1988, Faculty of Medicine, Galle. Abstract 13: 17.