

Occurrence of the lung fluke *Paragonimus macrorchis* Chen, 1962 in Ceylon

by

D. W. W. KANNANGARA

Department of Parasitology, University of Ceylon, Colombo

No cases of human paragonimiasis have been reported in Ceylon. Dissanaïke and Paramanathan (1962) reported the finding of *Paragonimus westermani*, the much dreaded human lung fluke of the Far East from a rusty spotted cat (*Felis rubiginosa*) and three leopards (*Panthera pardus*). They also found certain flukes in a civet cat (*Viverricula indica mayori*) and a fishing cat (*Felis viverrina*) which were provisionally identified as *P. compactus*. In this paper the author records *P. macrorchis* as the third species of the genus in Ceylon. This species was originally described in 1962 in China by Chen, and in Thailand by Miyazaki and Vajrasthira (1967).

The fluke was first isolated in the metacercarial stage in freshwater crabs and identification carried out after obtaining experimental adults. Two bandicoots (*Bandicota malabarica*) shot in the area where the infected crabs were collected was free of infection. The only snail found in the stream where most of the infected crabs were captured is a species of *Paludomus*. Work is being continued to establish the snail host and the natural definitive host.

The metacercariae (Fig. 1 and Plate I, C and D)

The freshwater crabs *Paratelphusa rugosa* (Plate I A) and a single specimen of *P. enodis* collected from the mountain streams at Upper Hantane overlooking the University campus at Peradeniya and two streams by the side of Gampola-Nuwara Eliya road in the Central Province, harboured a metacercaria predominantly in their hepatopancreas, also in muscle and rarely in gills which had a large number of red granules in the parenchyma. The ventral sucker is larger than the oral sucker which is sometimes provided with a small stylet. The excretory bladder reaches almost upto the intestinal bifurcation. These metacercariae are surrounded by thin fragile outer and inner cyst walls. With the movement of the metacercaria inside, the shape of the cyst wall changes becoming more oval when the metacercaria elongates and more spherical when it contracts. The cyst wall is so fragile that many are in the excysted form when first seen. One can visualise under a microscope how easily the metacercaria breaks through the cyst walls and becomes free, as it were by its own efforts within a few minutes of collection. The walls are so fragile that, they give way even under pressure of a small coverslip. Without coverglass pressure the inner cyst measures $337\mu/292\mu$ whereas the outer cyst measures $440\mu/357\mu$ on an average.

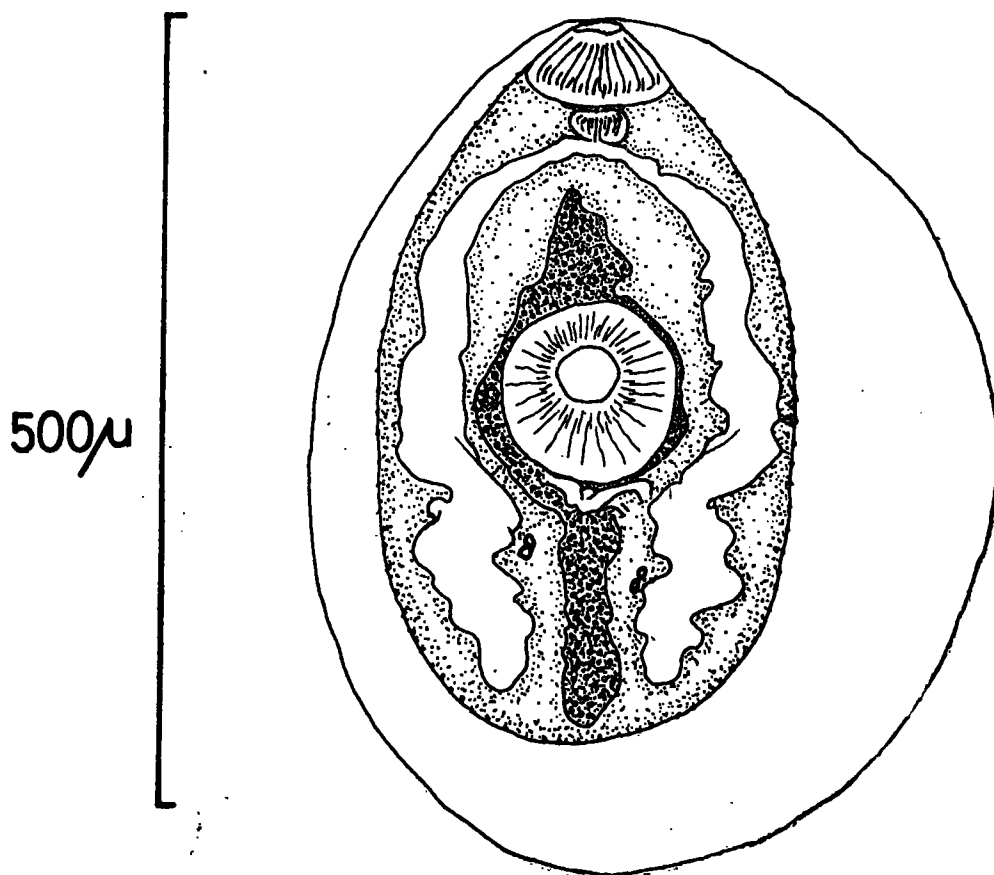


FIG. 1. Camera lucida drawing of *P. macrorchis* metacercaria with inner cyst wall from stained preparation.

TABLE I
Results of crab dissection

Species	Locality	No. of crabs	<i>P. macrorchis</i> + crabs
<i>Paratelphusa rugosa</i>	Upper Hantane (C.P.)	40	14
	32/11 Gampola-Nuwara Eliya Rd. (C.P.)	5	2
	4/9 Gampola-Nuwara Eliya Rd. (C.P.)	1	1
<i>P. cnodis</i>	Upper Hantane (C.P.)	1	1
	Total	47	18
	Incidence		38.3%

(The maximum number of metacercariae per host was 49)

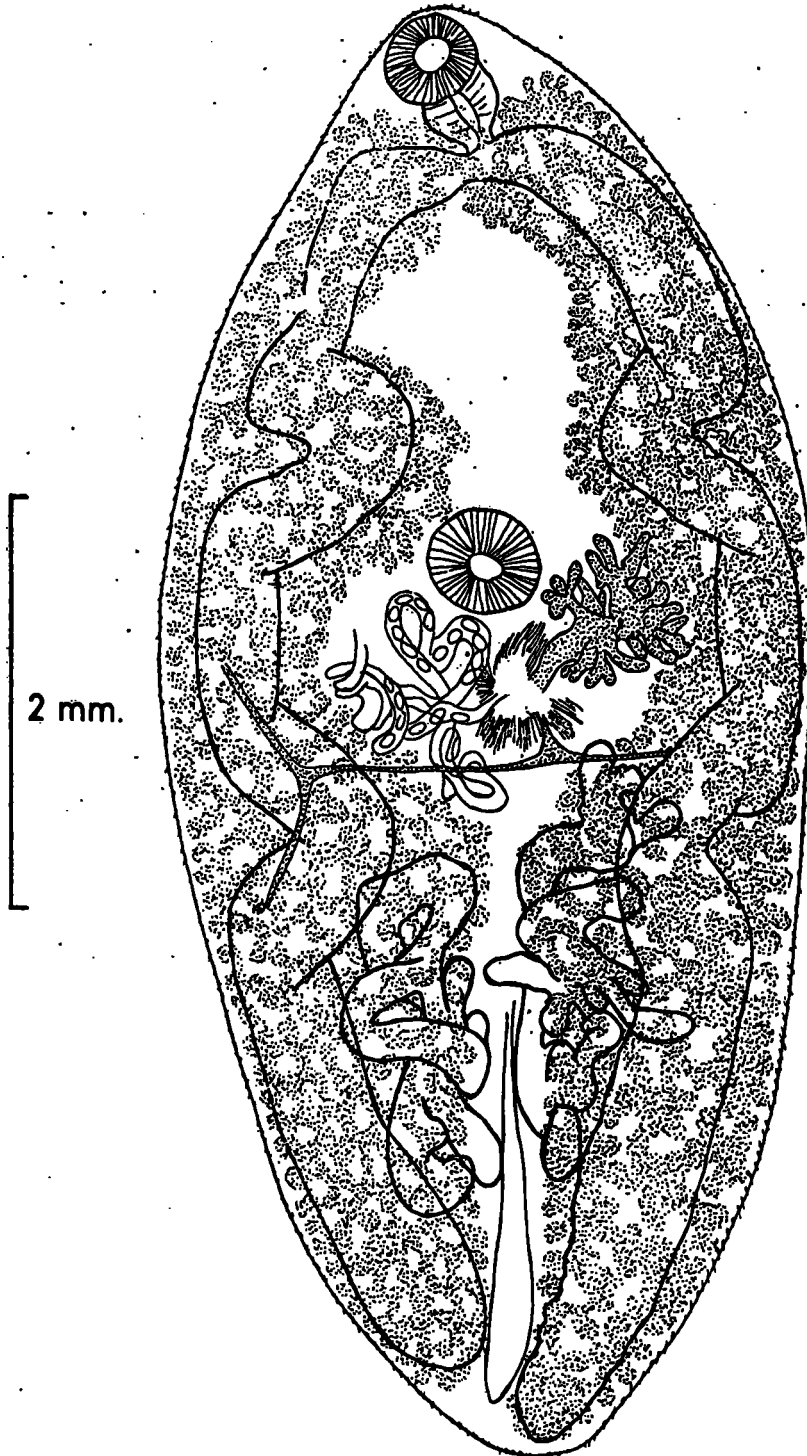


FIG. 2. Camera lucida drawing of adult collected from right pleural cavity of experimental dog.

The Experimental adults

The metacercariae collected were mostly in the excysted form. Experimental infections were produced in a pup, a cat and several albino rats by intraperitoneal injection of the excysted forms. Metacercariae with intact cyst walls were fed to rats. The details of the animals examined so far are as follows :—

1. The cat which was injected with 20 excysted metacercariae, died after 42 days. 8 immature worms were recovered from the pleural cavities. They were transplanted intraperitoneally into a rat. This rat was missing from the animal house and the experiment was lost.
2. The pup, which was injected with 15 excysted metacercariae, was examined after 97 days. At autopsy one small mature fluke was found in the right pleural cavity (Fig. 2 and Plate II E—G). The middle lobe of the right lung had a large cyst containing 3 large flukes.
3. A rat injected with 20 metacercariae was dissected after 47 days. The lungs were riddled with numerous *Paragonimus* cysts. One fluke was found crawling on the surface of the right lung. There were 5 large cysts in the right lung and 2 similar cysts in the left lung. 9 young adults were collected from this rat (Plate IV, K).
4. A rat injected with 8 metacercariae and dissected after 101 days, had 2 very large cysts in the left lung which were almost confluent (Plate IV, J) which harboured 3 and 2 worms respectively, while a single cyst in the right lung had 1 worm.

Morphology

The experimental adults are in various stages of development depending on the length of the experimental infection. The rat dissected on the 47th day had young adults with few ova in the uterus, whereas the worms recovered from the pup and the other rat are larger in size and in a more advanced state of maturation.

The measurements of 8, 47 day old worms are given in the table.

TABLE 2

(Measurements in mm.) Specimen No.	Length	Breadth	Oral sucker		Ventral sucker	
			Length	Breadth	Length	Breadth
1	4.82	2.53	.50	.48	.46	.48
2	5.96	3.28	.63	.55	.44	.48
3	5.33	3.04	.47	.55	.47	.49
4	4.16	2.44	.43	.48	.42	.44
5	6.10	3.33	.49	.57	.52	.53
6	5.30	3.30	.52	.40	.49	.53
7	7.70	4.20	.42	.46	.46	.48
8	6.50	4.00	.44	.58	.50	.50

These flukes have cuticular spines arranged in single (Plate II, G) which show longitudinal splitting. The oral sucker is almost equal to the ventral sucker in many specimens, though in some, one seems to be slightly larger than the other in one or more dimensions. The ovary is somewhat delicately branched and the testes are large and branched measuring .57 — 1.54 mm. long and .33 — 1.25 mm. broad in 47 day old specimens. 20 ova taken from the stool of an infected rat (Plate III, I) gives measurements ranging from 66.5 — 81.9 μ in length and 41.4 — 50.8 μ in breadth, the average being 73.7 μ /45.3 μ .

From the relative sizes of the oral and ventral suckers, the arrangement of the cuticular spines, the mode of branching of the ovary, the appearance of the testes and the morphology of metacercariae these specimens are identified as *P. macrorchis*.

PATHOLOGY

The pathological changes were studied in the dog and rat lungs.

Changes in the dog lung

Macroscopically the worm cyst is about the size of a grape, slate grey in colour and bulging above the pleural surface of the lung. On opening into the cyst by incising the fibrous wall a seropurulent fluid exudes which contains numerous *Paragonimus* ova. The inner cyst lining is uneven and irregular.

Microscopically the pleura shows accumulations of haemosiderin pigment laden cells. The lung shows slight emphysema, interstitial pneumonitis, areas of broncho-pneumonic consolidation and granulomatous lesions associated with numerous *Paragonimus* ova. (Plate III, H). Haemosiderin pigment laden cells (Fe +) are seen in large numbers in thickened alveolar septa and inside alveoli. A few small haemorrhages and subpleura foci of reaction around ova are present.

Changes in the rat lung

Macroscopically multiple cysts are seen in the rats studied so far. The gross appearance of each cyst is very similar to that of the lung cyst described from dog.

Microscopically a section of the left lung from the 1st rat shows two worms in a cyst cavity. The lung tissue adjacent to the cyst wall shows consolidation and accumulation of macrophages, mononuclear cells, a few polymorphs and granulomata containing numerous *Paragonimus* ova. Further away from the cyst cavity interstitial thickening and slight emphysema is seen.

DISCUSSION

So far *P. macrorchis* has been recorded only in the mainland of China and, more recently, in the Nakorn-nayok Province of Thailand (Miyazaki and Vajrathira, 1967). The metacercaria of this species is yet unknown in Thailand. The natural definitive hosts of this

fluke are rats and bandicoots in those countries. From the available evidence it appears that *P. macrorchis* is distributed in the hill country of the Central Province of Ceylon*. More work is needed to establish the natural definitive host and the first intermediate host. The role of *P. macrorchis* in human infection is not known.

SUMMARY

Two species of freshwater crabs *Paratelphusa rugosa* and *P. enodis* are found to be the second intermediate hosts of *Paragonimus macrorchis* which is recorded for the first time in Ceylon. These crabs were collected in the hilly area of the Central Province of Ceylon. Experimental infections in albino rats, a dog and a cat are described.

ACKNOWLEDGEMENTS

This work was supported by a research grant from the University of Ceylon, Colombo. The author wishes to thank Professor A. S. Dissanaïke for the facilities and guidance, Professor Ichiro Miyazaki, Department of Parasitology, Kyushu University, Japan and Dr. (Mrs.) D. Attygalle, Department of Pathology, University of Ceylon, Colombo for their opinion and suggestions. The technical assistance of Mr. G. M. S. Karunaratne during all stages of the study is much appreciated. The author also wishes to thank Mr. S. Nagamuttu for his help in search of the definitive host Mr. D. K. S. Chandrasome for tracing the drawings and typing the script, Mr. P. K. Gomes for photomicrographs, Mr. W. L. N. Perera for the assistance in crab collection, Mr. S. Marimuttu for looking after the experimental animals and Mr. R. C. de Silva who was helpful when crab dissections were in progress.


REFERENCES

- DISSANAÏKE, A. S. AND PARAMANANTHAN, D. C. (1962). *Paragonimus* infection in wild carnivores in Ceylon. *Ceylon. J. med. Sci.*, 11, 29—45.
- MIYAZAKI, I. AND VAJRASTHIRA, S. (1967) Occurrence of the lung fluke *Paragonimus macrorchis* Chen, 1962 in Thailand. *J. Parasit.*, 53, 894—895.

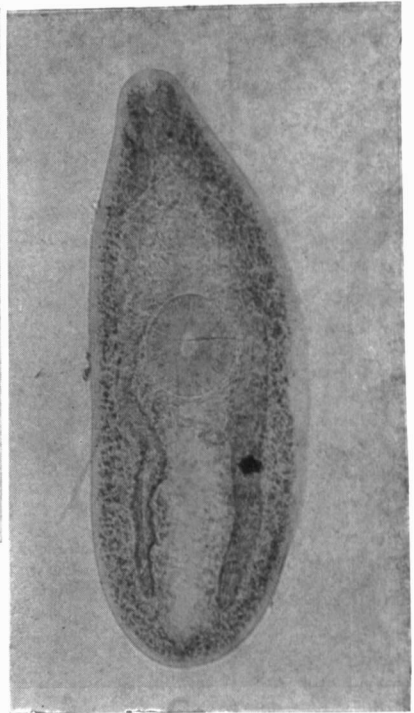
EXPLANATION OF PLATES

- PLATE I — A. *Paratelphusa rugosa*, the 2nd intermediate host of *P. macrorchis*.
 B. Lung cyst of *P. macrorchis* in experimental dog.
 C. Excysted metacercaria of *P. macrorchis*.
 D. Metacercaria of *P. macrorchis* with intact cyst walls.
- PLATE II — E. Ovary of *P. macrorchis* from experimental dog.
 F. Testes of *P. macrorchis* from experimental dog.
 G. Spines of *P. macrorchis* from experimental dog.
- PLATE III — H. Pathology of *P. macrorchis* infection in the experimental dog.
 I. Ovum of *P. macrorchis* from the stool of experimental rat.
- PLATE IV — J. Lung cyst of *P. macrorchis* from experimental rat.
 K. 47 day old adult of *P. macrorchis* from experimental rat.

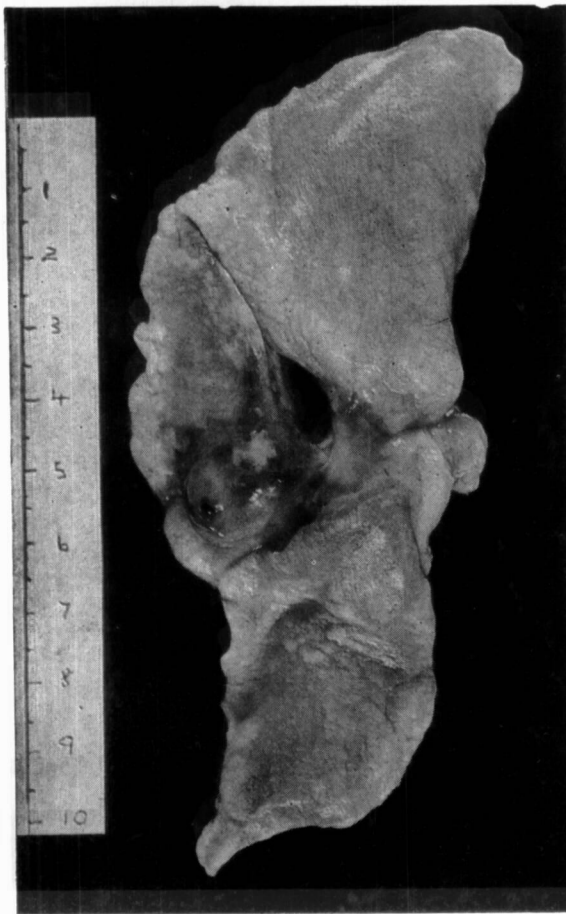
*More recently this infection was found in *P. rugosa* collected from two streams at Passara and Siyambalanda in the Uva Province.



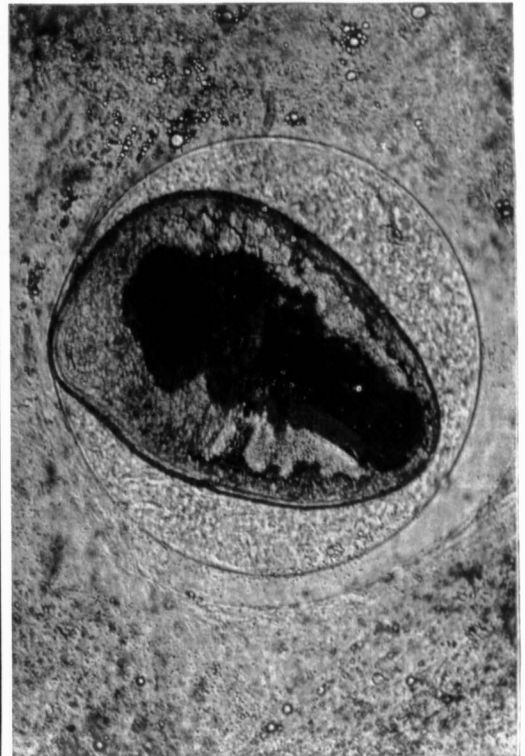
A



C

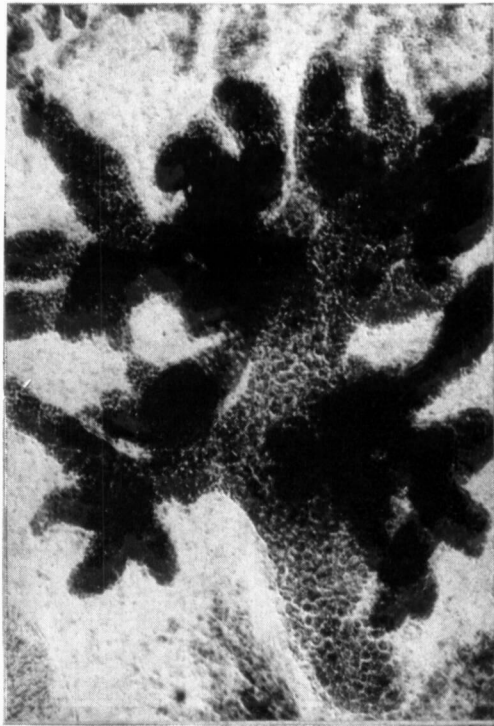


B

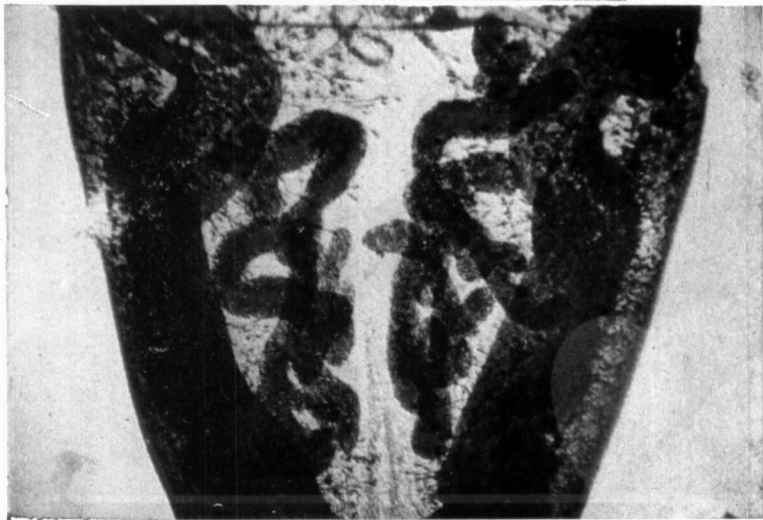

D

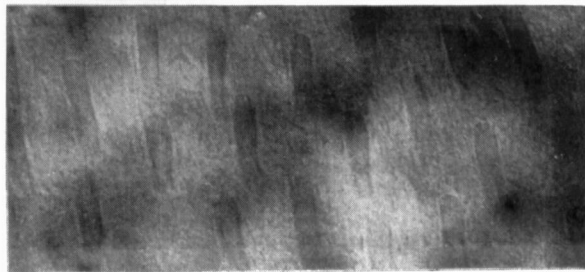
E



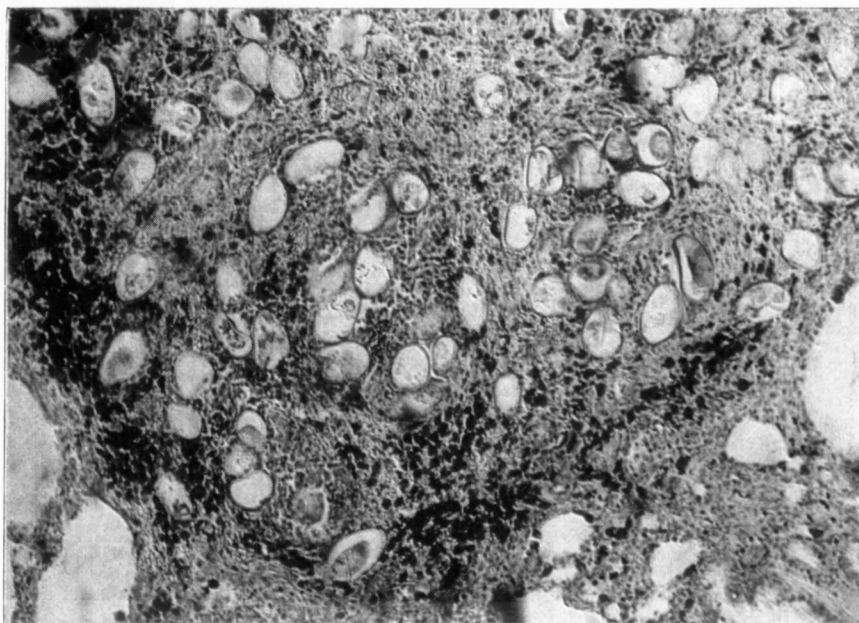
F



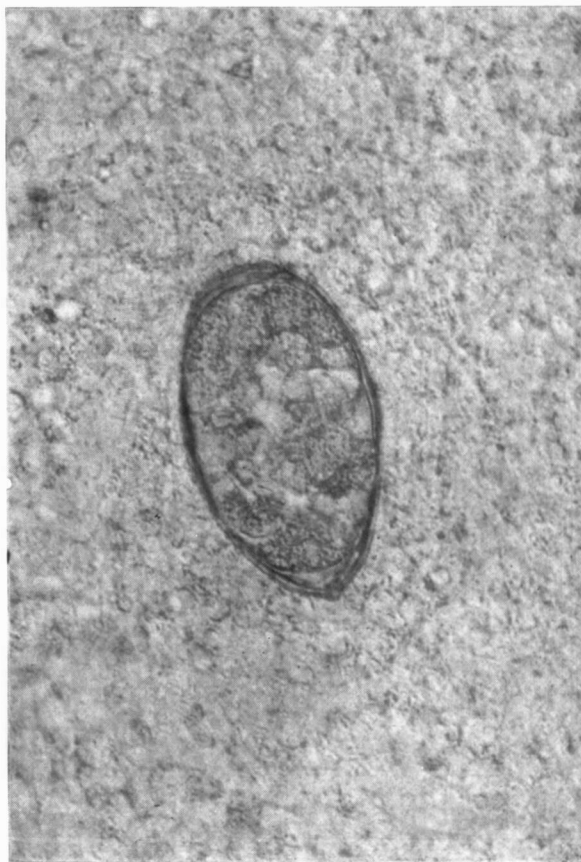G



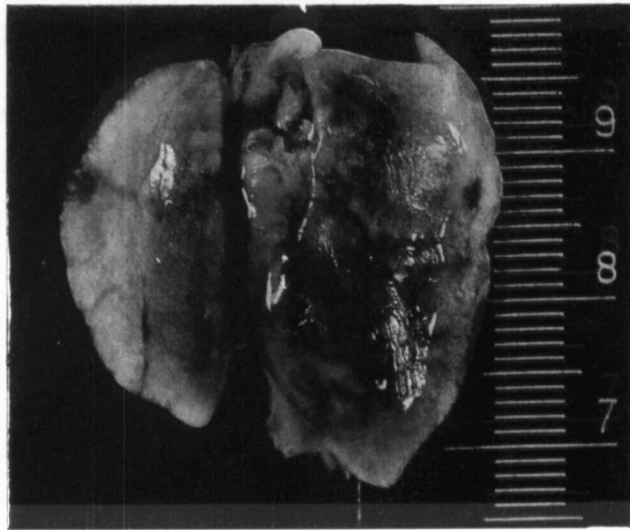
I



I



C



K

