

## Hepatoid yolk sac tumour of the ovary – a case report

N. R. Perera<sup>1</sup>, M. P. Kumarasinghe<sup>2</sup> and G. F. Sterrett<sup>3</sup>

*The Ceylon Journal of Medical Science* 1995; 38: 15-17

### Summary

Hepatoid Yolk Sac Tumour (HYST) of the ovary is an unusual but distinct tumour encountered in young women. The present case report was associated with extensive intra-abdominal metastases including the liver. The importance of identifying this tumour lies in its naturally aggressive behaviour and its resemblance, in certain aspects of its histology and immunohistochemistry, to the fibrolamellar variant of hepatocellular carcinoma and hepatoid carcinoma of the ovary.

**Key Words:** Ovary, Hepatoid Yolk Sac Tumour, Fibrolamellar variant of hepatocellular carcinoma, Hepatoid carcinoma.

### Introduction

The HYST was first described in 1982 by Prat and co-workers in a review of seven cases (1). The designation of HYST was given to an unusual type of ovarian germ cell tumour with a prominent or predominant histological pattern resembling that of the fibrolamellar variant of hepatocellular carcinoma (1,2). It is a tumour which occurs at a relatively young age, and may be associated clinically with amenorrhoea, hirsutism and virilism. We report the first case of hepatoid yolk sac tumour in Sri Lanka and emphasise the importance of recognising this entity, as the prognosis of this neoplasm appears to be poor.

### Case Report

A 19 year old Sri Lankan female presented with progressive abdominal swelling and secondary

amenorrhoea of 3 months duration. No virilising features were noted. Physical examination revealed a slightly-built, moderately nourished young female who had a firm, right-sided abdominal lump and hepatomegaly 3cm. No abnormality was found on examination of the other systems. A pre-operative ultra-sound scan of the abdomen showed a right-sided ovarian tumour with peritoneal and hepatic deposits. At laparotomy, a large nodular tumour measuring 18x17x9cm was found in the right ovary. Multiple secondary deposits ranging from 2-12cm in diameter were found in the peritoneal cavity, including the omentum, liver and the uterus.

The peritoneal cavity contained half a litre of blood stained ascitic fluid. A total abdominal hysterectomy with bilateral salpingo-oophorectomy and omentectomy was performed. The post-operative alpha-feto protein levels were moderately elevated (19.02IU/ml). The patient was referred for post-operative chemotherapy. She remained well for eight months and was re-admitted for a second-look laparotomy. A single secondary deposit measuring 2x1.5x0.5cm was found in the anterior abdominal wall. The liver, pelvis and bowel were found to be free of tumour, macroscopically. She died three months after the operation.

### Pathology

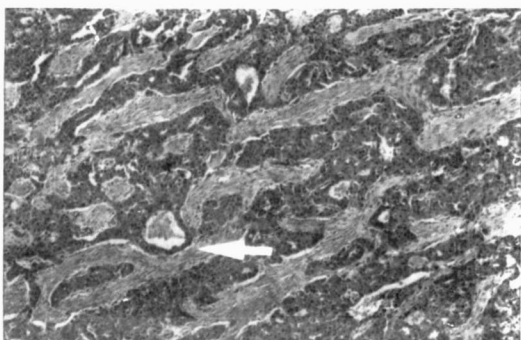
The right ovary contained a nodular mass measuring 18x17x9cm with a nodular outer surface. The cut surface was solid and pale in colour with necrosis and haemorrhage. The uterus contained an ipsilateral deposit in the

1 Lecturer 2 Senior Lecturer, Department of Pathology, University of Colombo, Colombo.

3 Clinical Associate Professor, Sir Charles Gairdner Hospital, Queen Elizabeth II Medical Centre, Perth, Western Australia

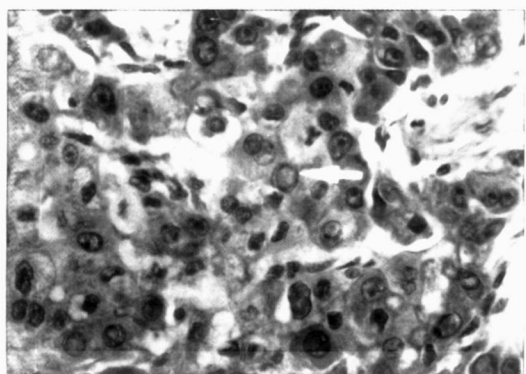
fundus measuring 6x4x4cms. The omentum and the liver contained several firm nodules ranging from 2-12cm in diameter. The left ovary was not found. Paraffin embedded haematoxylin and eosin stained sections revealed a tumour composed of solid sheets, trabeculae and gland like structures separated by fibrous septa (Fig. 1). The large polygonal cells showed abundant eosinophilic, granular cytoplasm, rounded nuclei with prominent nucleoli and intranuclear cytoplasmic inclusions (Fig. 2). Numerous intra and extra cytoplasmic hyaline globules were present and they were found to be PAS

Figure 1



Trabeculae and glandular structures (arrow) of large polygonal cells within a fibrous stroma (x 100)

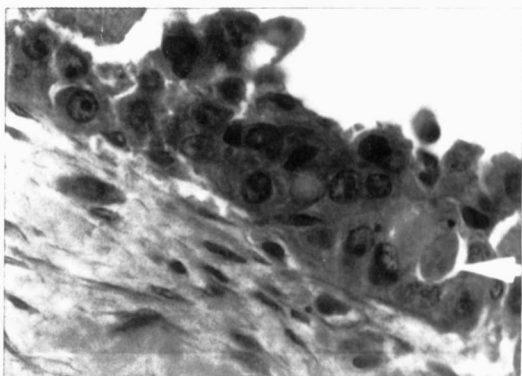
Figure 2



Polygonal cells with nucleoli and intranuclear inclusions (arrow) (x 400)

positive and diastase resistant (Fig.3). Immunohistochemical stains showed positivity for alpha I antitrypsin, CEA, AE 1+3 keratins and focal positivity for alpha-fetoprotein. HCG reaction was negative.

Figure 3



PAS positive diastase resistant intra and extracytoplasmic hyaline globules (arrow) (x 400)

None of the sections showed perivascular Schiller-Duval formations, cystic structures lined by a layer of flattened cells, or undifferentiated embryonal cells.

#### Discussion

Hepatoid yolk sac tumour was first described by Prat et al in 1982 (1). The present case described by us showed clinical, histopathological, histochemical and immunohistochemical features with striking similarity to those seen in the tumour designated as hepatoid yolk sac tumour. Our patient was a young female who presented with secondary amenorrhoea and a right-sided ovarian lump, which, on histological examination, showed an appearance mimicking a hepatocellular carcinoma, particularly the fibro-lamellar variant (Table 1). Her post-operative alpha-fetoprotein level was elevated. Therefore the possibility of a fibrolamellar variant of hepatocellular carcinoma (2), with ovarian and multiple intra-abdominal deposits was also considered.

**Table 1. Comparison of hepatoid yolk sac tumour with fibrolamellar variant of hepatocellular carcinoma**

	Fibrolamellar variant of hepatocellular carcinoma	Our patient
1. Age	Young adults	19 years
2. Ovarian lesions not documented	-	Primary tumour
3. Polygonal cells with granular eosinophilic cytoplasm	Present	Present
4. Fibrous stroma	Abundant	Present
5. Blood vessels within fibrous septa	Present	Sparse
6. Hyaline bodies	Present	Present
	PAS -ve	PAS +ve

This, however was thought to be less likely since the liver mass was much smaller than the ovarian tumour and the liver was completely free of tumour at the second-look operation. An extensive literature search failed to provide documentation of primary liver cell carcinoma producing extensive intra-abdominal and ovarian deposits. Another ovarian malignancy resembling a hepatocellular carcinoma is the hepatoid carcinoma of the ovary, first described by Inshikura and Scully in 1987 (3) (Table 2). All 5 cases documented by them occurred in a much later age group than our patient.

**Table 2. Comparison of hepatoid yolk sac tumour with hepatoid carcinoma of the ovary**

	Hepatoid carcinoma	Our patient
Age	42-78	19
Ovarian disease	None	Contralateral
Cellular uniformity	Usually absent	streak gonad present
Giant and bizarre cells	Usually present	Absent
Hyaline globules	Present	Present
Glandular structures	Rare	Present

No associated ovarian disease is seen in hepatoid carcinoma whereas our patient probably had a streak gonad. Most of the histological features observed were against a

diagnosis of hepatoid carcinoma. The presence of hyaline eosinophilic material between the tumour cells in a germ cell tumour is thought to be a very good indication of parietal yolk sac differentiation making our tumour a germ cell tumour and not an epithelial malignancy (4).

It is not unexpected to find hepatic differentiation in a yolk sac tumour, since both the yolk sac and the liver develop from the primitive gut. The association is reinforced by the fact that there are common proteins synthesised by both yolk sac tumour cells and liver cells, such as alpha-fetoprotein, alpha 1 antitrypsin, albumin and transferrin (1).

The importance of recognising this tumour lies in its poor prognosis (5), substantiated by the death of our patient eleven months after the initial diagnosis. In conclusion we designate this unusual ovarian neoplasm a hepatoid yolk sac tumour (endodermal sinus tumour with hepatoid differentiation) and report the first Sri Lankan case.

**References**

1. Prat J, Bhan AK, Dickersin GR, Robby SJ, Scully RE. Hepatoid yolk sac tumour of the ovary: a light microscopic, ultrastructural and immunohistochemical study of seven cases. *Cancer* 1982;50:2355-2368
2. Craig JR, Peters RL, Edmondson HA, Omata M. Fibrolamellar carcinoma of the liver: a tumour of adolescents and young adults with distinctive clinico pathologic features. *Cancer* 1980;40:372-379
3. Ischikura H, Scully RA. Hepatoid carcinoma of the ovary: a newly described tumour. *Cancer* 1987;60:2775-2784
4. Ulbright TM, Roth LM, Brodhecker CA. Yolk sac differentiation in germ cell tumours: a morphologic study of 50 cases with emphasis on hepatic, enteric and parietal yolk sac features. *The American Journal of Surgical Pathology*; 1986;10:151-164
5. Rosai J. ed. *Ackerman's Surgical Pathology* 7th St. Louis, 1989; p 1138-1139