

On Hare Lips and Cleft Palates

by

MILROY PAUL AND V. NAVARATNAM*

*Faculty of Medicine, University of Ceylon,
Colombo 8.*

The colloquial association between the common congenital cleft in the upper lip of babies and the midline cleft in the lip of animals, particularly of the hare, dates back to ancient times. Even today there are many who assume that the two clefts are of similar nature. Simple examination of a hare, however, reveals that the lip is not cleft through its entire thickness but that, at the edges of the 'cleft', the lip turns inwards to form a gutter. The skin on the lateral parts of the lip is hairy but it is moist and glabrous within the gutter. There is a similar glabrous epithelium on the nostrils continuous with that on the upper lip.

Boyd (1932, 1933), who studied the structure of the lips throughout the mammalian kingdom, has already drawn attention to the extension of the glabrous surface of the nostrils (the rhinarium) on to the median portion of the upper lip in several species. The shape and disposition of the glabrous segment of the lip do vary from species to species; for instance, in the hedgehog and in the lemuroids the glabrous segment is in the same plane as the lateral segments, whilst in other species as in the hare and the camel the glabrous segment is recessed into a gutter. Nonetheless, in virtually all mammals except the higher primates there is some interruption by the rhinarium in the surface of the upper lip. The reduction in the rhinial contribution to the lip in higher primates is probably related to the diminished tactile role of the region, with the disappearance of snout feeding, and is also in keeping with the increased protrusile capacity of the lips.

Although the human lip differs from that of lower mammals in that it does not possess a glabrous segment, it is characterised by the presence of the philtrum, which is a midline groove extending from the base of the nasal columella to the red margin. Unlike the rhinial segment in the lip of lower mammals, the human philtrum is covered by skin indistinguishable from that on the lateral parts of the lip. It is flanked on each side by a ridge sloping slightly outwards from the floor of the nostril, near the base of the columella, to the red margin of the lip where it determines the curve of Cupid's bow.

What is the homology between the configuration of the upper lip in man and that in other mammals? There are, broadly speaking, two views on the development of the human lip. One hypothesis, which was advanced by His (1892), is that the lateral parts of the lip are derived from the maxillary processes while the median portion (i.e. philtrum in man and rhinarium in lower mammals) arises from the fronto-nasal process; Peter (1913)

*Dr. Navaratnam's present address: Department of Anatomy, University of Cambridge, Cambridge, England.

and Warbrick (1960), both of whom like His studied serial sections through embryos, supported this hypothesis. On the other hand, Frazer (1931) postulated that each maxillary process extends to the midline and fuses with its fellow of the opposite side, thereby burying the fronto-nasal process; Frazer implied that his hypothesis would explain why the surface of the human upper lip is supplied by the maxillary nerves only, to the exclusion of the ophthalmic nerves which are generally associated with the fronto-nasal process.

In the present communication we have attempted to deduce the normal developmental processes by a study of congenital malformations of the lip and, in view of the frequent association between labial clefts and certain types of palatal defect, of the palate as well. Of course, investigations on similar lines have been previously conducted by other authors; in particular, the communications by Veau (1926, 1931) beautifully illustrate the consistent patterns exhibited by malformations of the lip and palate. It is the consistency of these patterns that necessitates their recognition in any adequate account of normal development. In a small minority of subjects, the cleft in the lip is an extension of an oblique facial cleft; these latter clefts, unlike the other commoner malformations, are often in the nature of irregular tears (Politzer, 1952) and hence their value as guides to normal development is doubtful.

MATERIAL

Our observations were made primarily on patients at the Lady Ridgeway Hospital for children, Colombo and at the General Hospital, Colombo. In addition, we were able to dissect specimens of many varieties of hare lip, cleft palate and cyclops at the museum of the Anatomy Department, University of Ceylon. When from time to time it became necessary to clarify certain aspects of normal anatomy, dissections were carried out on cadavers of normal foetuses, infants and adults.

OBSERVATIONS AND DISCUSSION

The site and extent of hare lip clefts

Unlike the upper lip of the hare, congenital hare lips are cleft through and through. They may be unilateral or bilateral, and the bilateral clefts suggest that the upper lip is formed from three components, notwithstanding the existence of midline clefts (*vide infra*). The clefts extend for a variable height from the red margin of the lip. A cleft is termed partial if it does not cut through the floor of the nostril (Fig. 1) and complete if it does (Fig. 2).

A partial cleft of the lip usually takes the form of a notch at the red margin. From the upper margin of the notch there is a furrow in the skin extending to the ipsilateral margin of the columella, along the line that the philtrum ridge should have occupied. It is of interest that, even in the occasional 'normal' person, during certain movements of the lips a furrow appears along the line of one of the philtrum ridges as though there is a cleavage in the musculature at that site; it is likely that this transient furrow represents an incipient cleft of the lip. At the other end of the scale, the severest type of partial cleft is one in which the deficiency invades, but does not cut through, the nostril rim (Fig. 3); to such a cleft the

term near-complete hare lip will be applied in this communication. In near-complete hare lips the red margin falls short of the upper reaches of the cleft. In other words, where the cleft involves the rim of the nostril, it is lined by ordinary skin. This thin bridge of skin between the cleft and the nasal orifice lacks the rigidity of the normal nostril and, consequently, is considerably stretched.

The variable height of a hare lip cleft, from the red margin to the floor of the nostril gives evidence that the median and lateral components of the lip coalesce, under normal circumstances, from the nostril towards the mouth.

Unilateral complete or near-complete hare lips have no philtrum ridge on the side of the cleft. There is, however, a philtrum ridge on the opposite side (Fig. 2) and, medial to the ridge, there is a strip of skin which represents the philtrum. In bilateral complete (Fig. 4) and near-complete hare lips there is no philtrum ridge on either side. The skin on the front surface of the median component is flat and would represent the philtrum in such cases. These features of the different varieties of hare lip give evidence that the clefts occur along the lines of the philtrum ridges.

The occurrence of median clefts is often cited as evidence against the tripartite configuration of the upper lip. However, many of the so-called median clefts are really bilateral hare lips in which the median component is so rudimentary as to allow the two clefts to run together; there are no philtrum ridges in these subjects. On the other hand more problematic is the very uncommon occurrence of a true midline cleft, usually partial, situated unmistakably between the two philtrum ridges (Fig. 209C of Hamilton, Boyd and Mossman (1962) illustrates such a case). Nevertheless, we are convinced that this anomaly is compatible with the idea that the philtrum ridges demarcate three primary components of the upper lip and that the midline cleft is an expression of the binary nature of the median component itself (*vide infra*).

Although there is considerable distortion in a hare lip, the fraenum is invaluable in determining the true midline. In bilateral hare lips the fraenum attaches the median component or tubercle to the alveolus of the jaw behind. In unilateral hare lips the fraenum is attached to the lip on the medial side of the cleft i.e. between the cleft and the single philtrum ridge.

It is of interest to inquire how the disposition of the Orbicularis Oris muscle is altered by the presence of a cleft in the upper lip. Dissections carried out on fresh cadavers revealed that, apart from a fascicle which crosses the midline near the red margin, the normal Orbicularis Oris arises mainly as two diverging heads (Fig. 5), each of which has a continuous origin from the lower face of the nasal columella and from the lower edge of the nostril. These two heads sweep downwards and outwards like the two halves of a moustache and, as they diverge, each lies subjacent to the philtrum ridge. The philtrum ridge itself is raised by a condensation of fibro-fatty tissue lying between the skin and the muscle.

Observations on the directions of muscle fibres at the edges of hare lip clefts were made during operations for the repair of these deformities. In unilateral complete or near-complete hare lips, a whole head of the Orbicularis muscle is compressed to a thin belly arising where the lower end of the nostril junctions with the lateral margin of the cleft in the lip proper (Fig. 6). The other head of the Orbicularis has its normal wide origin and lies on the medial side of the cleft. These abnormalities in the disposition of the muscle probably account for much of the distortion in unilateral hare lips. The ipsilateral nostril is splayed out by the pull of the muscle belly attached to its lower end while the base of the columella is tilted to the opposite side by the unopposed action of the contralateral normal head of the Orbicularis. It is worth mentioning that even in unilateral partial clefts of the lip the base of the columella is often deviated away from the notch, suggesting that the musculature lateral to the cleft fails to reach the columella.

In bilateral complete and near-complete hare lips the heads of the Orbicularis Oris are compressed to two narrow bellies attached to the lower ends of the splayed out nostrils. Biopsy material taken at surgical operation from eleven subjects, comprising eight infants and three older children, failed to reveal any musculature in the median component. These observations indicate that during normal development the musculature migrates through the lateral components of the upper lip into the median component and that migration into the latter is prevented by clefts. Although King (1954) observed in a specimen with bilateral hare lips that branches of the infraorbital nerves entered the median component of the lip by way of the nasal columella, there is no evidence that muscle migrates along this pathway.

The site of clefts in the palate

Palates may be cleft either in the midline from the tip of the uvula towards the incisive fossa or from immediately behind a hare lip cleft, on one or both sides, through the alveolus of the jaw to the incisive fossa. The latter clefts are in fact more than clefts of the palate; they are clefts of the upper jaw passing between the medial and lateral incisor teeth or, less frequently, between the incisors and the canine. If the midline cleft of the palate and the two anterior clefts of the jaw are of full extent, they would divide the upper jaw into three components, a triangular median component and two lateral components.

Midline palatal clefts extend for varying distances from the tip of the uvula towards the incisive fossa, giving evidence that the palate at this place is formed by the union, from the incisive fossa backwards, of the edges of the two palatal shelves. Midline clefts of the palate may occur with or without an associated cleft in the lip or an anterior cleft in the upper jaw, thus showing that arrest of union of the palatal shelves is independent of arrest at the hare lip grooves. On the other hand, anterior clefts in the upper jaw are always behind a hare lip cleft, even though hare lips may occur without clefts in the upper jaw. Anterior clefts of the upper jaw are, therefore, deeper extensions of hare lip clefts. Stark (1961) also has drawn attention to the congruity of hare lip clefts and anterior clefts of the jaw.

The maximal displacements between the components of the upper jaw occur in cases of bilateral anterior clefts of the jaw (see Fig. 4). Such clefts are, in our experience, invariably associated with bilateral complete clefts in the upper lip. For this reason and, moreover, because the nasal septum which is continuous with the median component usually fails to become attached to the palatal shelves, there is virtual isolation of the median component of the upper jaw and lip from the lateral components. The median component of the jaw, with the median component of the upper lip perched in front of it projects beyond and above the lateral components. As a result of compression between its natural upward thrust and the downward pull exerted on the point of the nose by the tautly stretched nostrils, the median component is often suppressed in growth to a grotesque degree.

Considerable displacement occurs also at the site of unilateral clefts of the upper jaw, where the median component projects beyond and above the lateral component on the affected side. As the alveolus of the median component approaches the site of displacement its projection beyond the normal arc results in a typical curl (see Fig. 2); the teeth on the curled section of the alveolus point towards the line of displacement. In cases of unilateral anterior cleft of the jaw with a complete midline cleft of the palate, the nasal septum is attached to the median component and behind this, if at all, to the palatal shelf on the normal side.

Some embryological concepts

It is generally accepted that, during early embryonic development, there is an elevation or hood overhanging each nasal orifice. In fact, these hoods do more than circumscribe the nasal orifices (Fig. 7). Each hood consists of a vertical stem and a laterally directed loop at the upper end of the stem. The vertical stem ascends, on each side of the middle line, from the upper margin of the stomodaeal orifice; it then loops laterally round the corresponding nasal orifice and junctions with the side of the vertical stem.

The vertical stems are referred to, in embryological writings, as the medial nasal processes and the laterally directed loops are referred to as the lateral nasal processes. However, this terminology is unrealistic because there is no discontinuity between the vertical stems and the loops. The term nasal hood, to include each vertical stem and the lateral loop, is more representative of the true picture. The laterally directed loops become the definitive nostrils and the vertical stems on the two sides join to form the nasal columella, at the level of the loops, as well as the median components of the upper lip and jaw, below the level of the loops. The significance of the formation, from part of the nasal hoods, of the median components of the upper lip and jaw becomes evident in the light of the knowledge that in all mammals, except the higher primates, the glabrous epithelium on the nostrils continues on to the median segment of the upper lip. Although man like the other higher primates has no rhinarium, the disposition of the nasal hoods in the early human embryo indicates evolution through a rhinarium stage.

The vertical stems of the nasal hoods are flanked by the incurled ends of the laterally directed loops and, immediately below these loops, by the medial extremities of maxillary elevations. The grooves along the lateral borders of the vertical stems are the grooves at

which clefts of hare lips occur and, for convenience, they will be referred to as the hare lip grooves. At each hare lip groove, there is initially no packing of mesodermal tissue; the surface ectoderm lies in contact with the mucous membrane of the stomodaeum along this line. During normal development, mesoderm grows in and obliterates the groove but, if it fails to do so, the surface ectoderm and the subjacent mucous membrane may break down to give a hare lip cleft (Veau, 1938). Other hypotheses on the pathogenesis of hare lips have been advanced (see Warbrick, 1960 and Töndury, 1961 for reviews) but Veau's explanation accords best with the known facts.

The structures junctioning at the hare lip grooves are in two tiers. The upper tier, where the conjoined vertical stems of the nasal hoods junction with the medial ends of the incurled lateral loops, differentiates into the site at which the nasal columella junctions the floor of the nostril on each side. The lower tier, where the vertical stems junction with the maxillary elevations, differentiates into the median component of the upper lip and the lateral components of the upper lip and, on a deeper plane, into the median component of the upper jaw and the lateral components of the upper jaw. A cleft at the lower tier is a cleft between the median and lateral components of the upper lip and, if it extends deeper, it is a cleft between the median and lateral components of the upper jaw. A cleft at the upper tier of the hare lip groove is, as has been pointed out earlier, always an extension from a cleft at the lower tier and it will open into the nasal orifice between the base of the nasal columella and the floor of the nostril.

Cyclops

Useful information on the mechanics of clefts at the hare lip grooves was obtained from specimens of human cyclops, of which four were available. In these specimens, the nasal pits are rudimentary and lie just below the base of the skull, often included in a proboscis like structure. It can be surmised that in these specimens the nasal hoods have lost all attachment to the maxillary elevations; hence the nasal apertures remain near the base of the skull, instead of being drawn near the stomodaeal orifice when the maxillary elevations increased in height to form a face. The developing eyes below the nasal pits are fused, to a greater or lesser extent, forming a cyclops eye (Fig. 8). The medial extremities of the maxillary elevations may, exceptionally, remain apart thus leaving a midline cleft in the lip but, in the majority of specimens, the maxillary elevations converge below the cyclops eye to form an intact lip; as far as we can ascertain, however, such a lip is devoid of a fraenum and philtrum and philtrum ridges, presumably because it has no median component from the vertical stems of the nasal hoods. For the same reason it may be surmised that there should be no median component in the upper jaw. Examination of the dissected palate of two cyclopean monsters revealed that this is indeed the case. The incisive fossa, which is so prominent a feature in the normal infant palate, is not recognisable in the cyclops palate which has two lateral components only. The alveolus of each lateral component bears its usual complement of three tooth germs i.e. a canine and two molars. From time to time there have been reports in the literature (see Boyd & Miles, 1951) of specimens of cyclops with a midline tooth germ between the two canines; such an occurrence should be interpreted in the same light as a midline supernumerary tooth in an otherwise normal individual and not as representative of the median component of the upper jaw.

SUMMARY

1. Study of several varieties of hare lip in man indicates that these clefts occur along the lines of the philtrum ridges. All grades of hare lip are associated with distortion of the nostrils and with disruption in the musculature of the Orbicularis Oris.
2. Anterior clefts of the upper jaw do not occur in the absence of corresponding hare lips and should be regarded as deeper extensions of the latter. Median clefts of the palate, on the other hand, are unrelated to hare lips.
3. The patterns of malformation suggest that the upper lip and upper jaw are each developed from three components. A median component derived from the fronto-nasal process and two lateral components derived from the maxillary processes. The fronto-nasal process itself is bipartite during the early stages of development, being composed of two nasal hoods, and its binary nature occasionally expresses itself in the very uncommon median cleft of the upper lip.
4. In specimens of cyclops, the upper lip and upper jaw are devoid of their median segments.

ACKNOWLEDGMENTS

It is a pleasure to acknowledge the help of Dr. M. Thambirajah and Mr. S. G. Weerasooriya, who helped in the collection of the clinical data and did much of the spadework, and of Mr. P. D. S. Amarasekera and Mr. A. S. Mahawatta, who rendered the photographs. The authors are also greatly indebted to Professor J. D. Boyd for his comments on the script and for drawing their attention to several important papers on the subject.

REFERENCES

- BOYD, J. D. (1932). A contribution to the comparative anatomy and embryology of the mammalian lips. M.Sc. thesis, Queen's University of Belfast.
- BOYD, J. D. (1933). The classification of the upper lip in mammals. *J. Anat.*, **67**, 409—416.
- BOYD, J. D. AND MILES, A. E. W. (1951). An erupted tooth in a cyclops foetus. *Br. dent. J.*, **91**, 173—181.
- FRAZER, J. E. S. (1931). *Manual of Embryology*. 1st ed. London: Baillière, Tindall & Cox.
- HAMILTON, W. J., BOYD, J. D. AND MOSSMAN, H. W. (1962). *Human Embryology*. 3rd ed. Cambridge: W. Heffer & Sons.
- HIS, W. (1892). Die Entwicklung der menschlichen und thierischer Physiognomien. *Arch. Anat. Physical.*, 384—424.
- KING, T. S. (1954). The anatomy of hare-lip in man. *J. Anat.*, **88**, 1—12.
- PETER, K. (1913). *Atlas der Entwicklung der Nase und des Gaumens beim Menschen*. Jena: Fischer.
- POLITZER, G. (1952). Zur normalen und abnormen Entwicklung des menschlichen Gesichtes. *Z. Anat. Entw.-Gesch.*, **116**, 332—347.
- STARK, R. B. (1961). Embryology, pathogenesis and classification of cleft lip and cleft palate. In *Anomalies of the Face and Associated Structures*. Ed. S. Pruzansky. Springfield: C. C. Thomas.
- TÖNDURY, G. (1961). On the mechanism of cleft formation. *ibid.*
- VEAU, V. (1926). Le rôle du tubercule médian dans la constitution de la face. *Annls Anat. path. Anat. norm. méd.-chir.*, **3**, 305—348.
- VEAU, V. (1931). *Division Palatine*. Paris: Masson et Cie.
- VEAU, V. (1938). Hasenscharten menschlicher-Keimlinge auf der Stufe 21—23 mm. S. St. L. *Z. Anat. Entw.-Gesch.*, **108**, 459—493.
- WARBRICK, J. G. (1960). The early development of the nasal cavity and upper lip in the human embryo. *J. Anat.*, **94**, 351—362.

Fig. 1

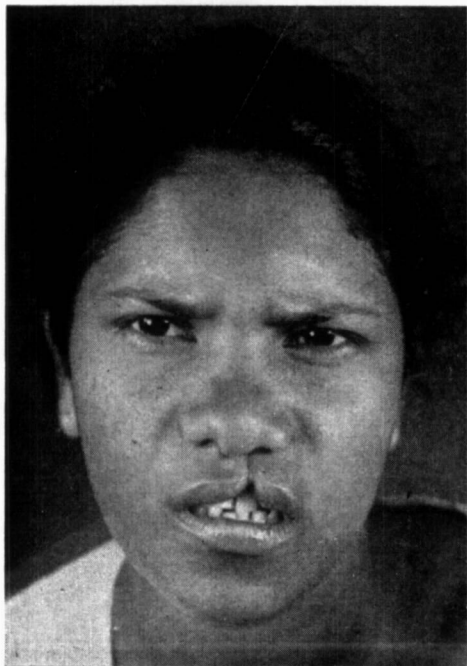

Fig. 2

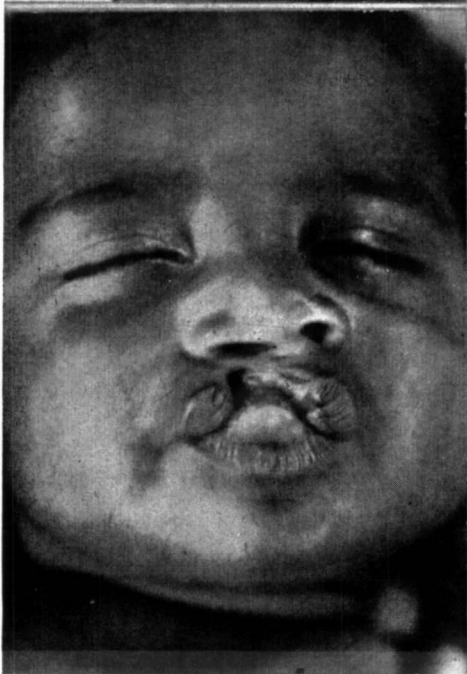
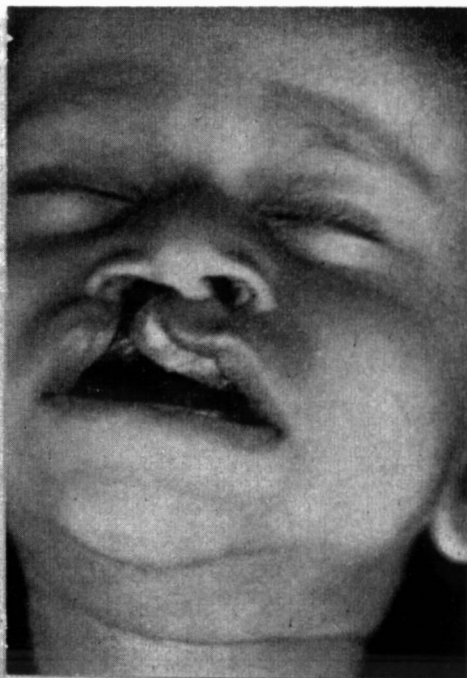

Fig. 3




Fig. 4

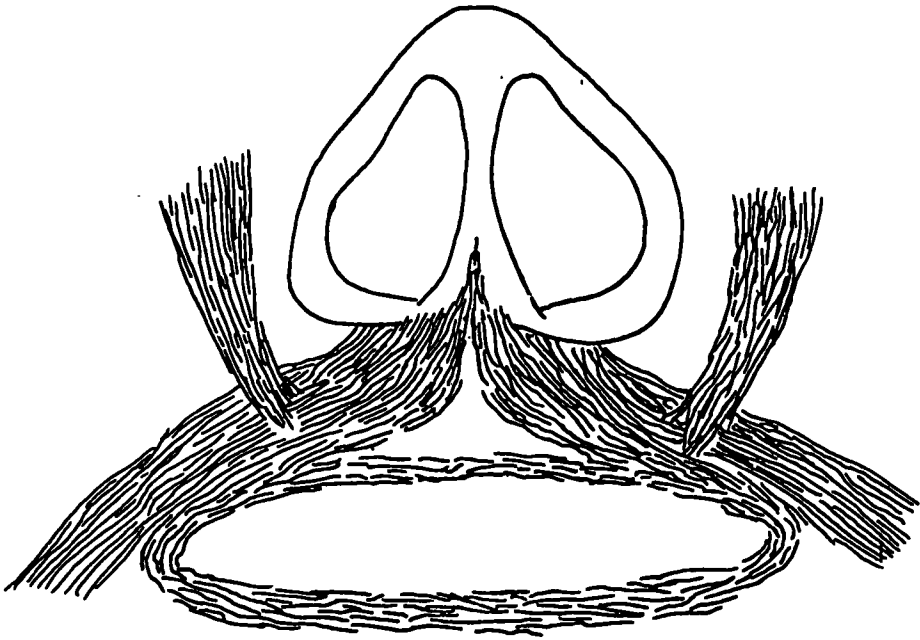


Fig. 5

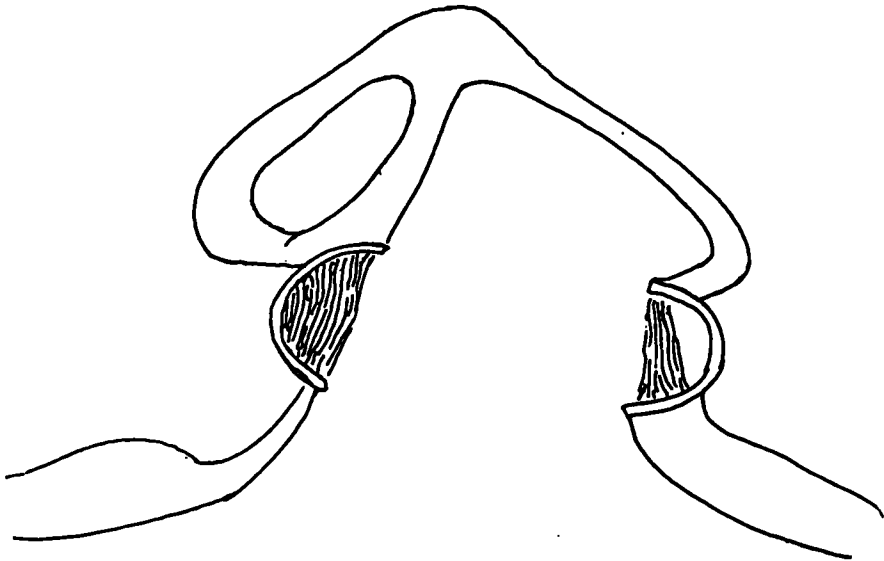


Fig. 6

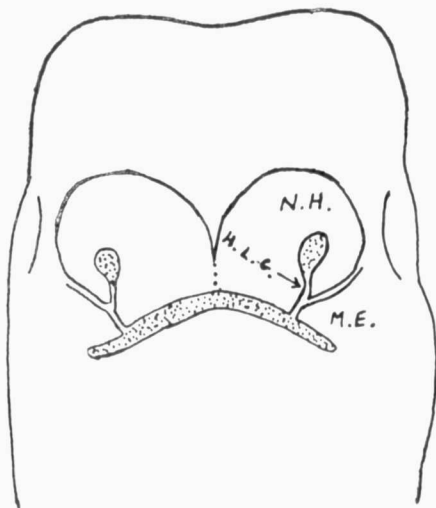


Fig. 7

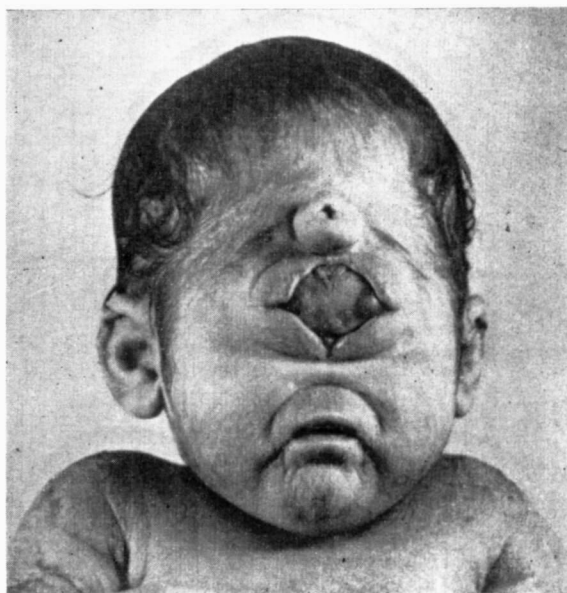

Fig. 8

EXPLANATION OF PLATES

PLATE I

- Fig. 1. An adult with a unilateral partial cleft of the lip. From the upper end of the notch there is a furrow extending to the floor of the ipsilateral nostril. This furrow probably represents a cleavage in the underlying musculature as is indicated by the distortion of the nostrils.
- Fig. 2. A child with a unilateral complete hare lip with a concomitant unilateral cleft of the jaw. Note the curl of the alveolus on the medial side of the cleft and the distortion of the nostrils.
- Fig. 3. A child with a unilateral near-complete hare lip. Note the distortion of the nostrils.
- Fig. 4. A child with bilateral complete hare lips with concomitant bilateral clefts in the jaw.

PLATE II

- Fig. 5. Diagram showing the disposition of the Orbicularis Oris muscle in a normal individual.
- Fig. 6. Diagram showing the disposition of the Orbicularis Oris in a person with a unilateral complete hare lip.

PLATE III

- Fig. 7. Diagram of the face of a 10 mm. C. R. human embryo showing the disposition of the nasal hoods (N.H.). Each nasal hood consists of a vertical stem continuous with a lateral loop which circumscribes the nasal orifice. At the hare lip groove (H.L.G.), each vertical stem junctions with the uncurled end of the lateral loop and, more caudally, with the medial end of the ipsilateral maxillary elevation (M.E.).
Modified from Hamilton, Boyd & Mossman (1962).
- Fig. 8. A specimen of cyclops with proboscis.