

## Tuberculous myocarditis – An unusual presentation

P. Angunawela<sup>1</sup>, S. Lamabadusuriya<sup>2</sup> and C. De Alwis<sup>3</sup>

*The Ceylon Journal of Medical Science 1994; 37: 29-30*

### Summary

The case history of a child presenting with heart failure due to tuberculosis is discussed. Histological examination and post-mortem revealed miliary tuberculosis of the lung, liver and spleen. The heart muscle was involved diffusely by a layer of caseous granulomatous infiltrate, replacing a major part of the myocardium.

The unusual feature was diffuse involvement of the myocardium and absence of tubercles on the pericardial surfaces of the heart.

**Key Words:** Tuberculosis, Myocarditis

### Case Report

A seven year old boy was admitted to the Lady Ridgeway Children's Hospital, Colombo, with a history of swelling of both legs and puffiness of face of one week duration. He had been quite unwell for 1 month prior to admission with cough and loss of appetite.

He was from a poor socio-economic background and the mother was suffering from pulmonary tuberculosis. His nutritional status was poor and the body weight was only 9 kg. He also had oedema of both legs and external genitalia. The pulse, blood pressure and heart sounds were normal. No abnormality was detected clinically in the respiratory system. The liver was enlarged 1 finger below the costal margin and the spleen was not palpable. Clinically a diagnosis of kwashiorkor was made. The child was given a plasma transfusion and he expired 8 hours after admission to hospital.

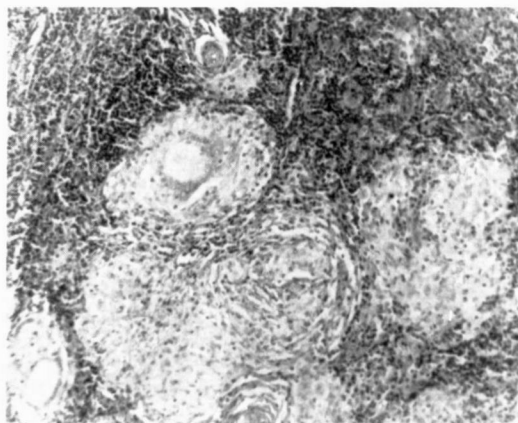
The post-mortem examination revealed straw coloured free fluid in the pleural and the peritoneal cavities. A few patches of

consolidation were seen in the perihilar region and calcified lymph nodes were seen in the hilum. The heart was enlarged, globular and weighed 400 g. Both ventricles were hypertrophied.

The thickness of the left ventricular muscle was 2 cms. The cut surface of the ventricular muscle revealed 1.7 cms thick, whitish, band-like areas replacing a major part of the muscle. Tubercles were not seen and no congenital abnormality was detected.

Histological examination of the heart showed large areas of caseation, and epithelial cell granulomatous infiltrate (Fig. 1). Ziehl Neelsen stain revealed acid fast – bacilli. The lung, liver and spleen showed very small miliary type granulomata.

**Fig. 1**



Section of the myocardium showing epithelioid cell granulomas stained with haematoxylin and eosin (x 200).

<sup>1</sup> Senior Lecturer, Department of Pathology

<sup>2</sup> Professor of Paediatrics

<sup>3</sup> Registrar, Department of Paediatrics, Faculty of Medicine, University of Colombo, Colombo 8.

### Discussion

The immunological response to Matoux could not be elicited. However due to undernutrition, it could be assumed that his defensive immunological mechanisms were depressed and secondary infection could have been triggered by exposure to large doses of exogenous bacteria.

The presences of small granulomas in organs like liver, lung and heart are highly consistent with miliary tuberculosis. Absence of pericardial lesions and tubercles on the surface of the heart, and diffuse involvement of the myocardium were unusual features. Tuberculous myocarditis occurs in three different forms, nodular (or tuberculoma) miliary and the diffuse (1). Of these three the commonest presentation is the nodular form. In a study conducted by Rose (2) out of 19 patients, at post-mortem examination, 8 had miliary lesion and 11 had nodular lesions in the myocardium. Chang and Dickens (3) and Leon - Pena *et al.* (4) have reported patients presenting as heart failure and sudden cardiac death with presence of miliary lesions in the myocardium.

With miliary tuberculosis diffuse lesions in the myocardium have not been reported.

Though miliary tuberculosis is not as common as in the past it remains one of the possible causes of sudden cardiac death.

The frequency of this pathology, the uncommon clinical presentation and the unusual distribution of lesions in the myocardium should be noted.

### Acknowledgements

We wish to thank Dr. Dilani Lokuhetty and Miss Sandya Nanayakkara for the assistance in the preparation of this paper.

### References

1. Cortran R S, Kumar V, Robbins S L. Pathologic Basis of Disease, 4th Edition, Philadelphia: W B Saunders, 1986, p. 376.
2. Rose A G: Cardiac Tuberculosis. A study of 19 patients. Archives of Pathological Laboratory Medicine, 1987; 111(5): 422-6.
3. Chang A C, Dickens P.; Tuberculous myocarditis presenting as sudden cardiac death. Forensic Science International, 1992; 57(1): 45-50.
4. Leon-Pena A, Stanislawsky M E, Saenz A G, Ruiz M V, Gozaliz C V M, Bernal M A. Tuberculous myocarditis: Presentation of a case and review of the literature. Archives of Internal Cardiology, 1989; 59(5): 511-6.